Neural and Neuroendocrine Neoplasms (Other than Neurofibromatosis)

115

Andrea Saggini, Tomoko Akaike, Paul Nghiem and Zsolt B. Argenyi

Chapter Contents

Classification, Terminology, and Histogenesis 2077
Neuromas 2077
Schwannoma 2081
Neurofibroma. 2083
Nerve Sheath Myxoma and Cellular Neurothekeoma. 2084
Granular Cell Tumor 2085
Perineurioma 2086
Malignant Peripheral Nerve Sheath Tumor 2087
Merkel Cell Carcinoma 2087
Heterotopic Neural Tissue of the Skin. 2090
Primitive Neuroectodermal Tumors 2092

In the past, neural tumors were often misdiagnosed histopathologically because of confusing classifications. As a result, their clinical relevance was poorly understood. Clinically, cutaneous neural tumors often look alike and most of them are benign. However, their correct diagnosis can be helpful in recognizing important clinical syndromes and this can contribute to better patient management[1].

CLASSIFICATION, TERMINOLOGY, AND HISTOGENESIS

Cutaneous neural tumors can be classified into two major groups: those derived from peripheral nerves and those derived from ectopic or heterotopic neural tissue (Table 115.1). The former group were classically subdivided into true nerve sheath neoplasms and hamartomatous tumors, although this classification may be specious due to evidence that most hamartomas are driven by clonal expansion of a neoplastic cell population[2,3].

Cutaneous neural tumors tend to differentiate toward one or more elements of the nervous system; as a result, they recapitulate to varying degrees the morphogenesis of normal peripheral nerves. Therefore, knowledge of the organization of the normal peripheral nerve (Fig. 115.1) is crucial to understanding the histogenesis of cutaneous neural tumors[2].

The basic element of a peripheral nerve is the nerve fiber, which is composed of an axon and its surrounding Schwann cell layer. A peripheral nerve can be compared to a conventional telephone cable, in which each axon and its surrounding Schwann cell layer correspond to a telephone wire and its insulation, respectively. Nerve fibers are bundled within nerve fascicles by the perineurium, a sheath composed of specialized perineurial cells (see Fig. 115.1). Inside the nerve fascicle, the space between individual nerve fibers is referred to as the endoneurium. The bundles of nerve fascicles are further encased in a supportive fibrous sheath called the epineurium. To a variable extent, this architectural arrangement is recognizable in many cutaneous neural neoplasms.

The most important constituent cells are the Schwann cell, the perineurial cell, and the various nonspecific mesenchymal cells, such as fibroblasts and mast cells. These cells are capable of proliferation and malignant transformation. Other elements of the peripheral nerve, which are cell parts or products (i.e. axons and myelin, respectively), cannot duplicate. Schwann cells are derived from the neural crest and perineurial cells appear to be modified fibroblasts of mesodermal origin. This difference in histogenesis is also reflected in the distinct antigenic expression of these cells. Schwann cells express S100 protein and SOX10 but not perineurial markers (e.g. epithelial membrane antigen, GLUT1, claudin-1), whereas perineurial cells stain positively for perineurial markers but not S100 protein and SOX10. Axons contain a specific type of intermediate filament called neurofilament, and myelinated axons contain myelin basic protein, both of which can be detected by immunohistochemistry. These and other immunohistochemical markers often can help to establish the correct diagnosis.

In the following sections, each clinically relevant neural neoplasm is discussed (Tables 115.2–115.4).

NEUROMAS

Key features

Traumatic neuroma

- Develops at the site of previous trauma
- Skin-colored papule or nodule that is often painful or sensitive
- Circumscribed histologically, but not encapsulated
- Regenerative proliferation of axons and Schwann cells within fibrous scar tissue

Solitary circumscribed neuroma

- Formerly known as "palisaded encapsulated neuroma"
- Solitary papule or nodule, usually on the face of adults
- Circumscribed histologically; partially or completely encapsulated
- Compactly arranged fascicles of spindle cells with only vague palisading of nuclei

Introduction

Neuromas are proliferations of neural tissue in which the ratio of axons to Schwann cells is only slightly less than the normal 1 : 1 ratio. There are two major subtypes: *traumatic (or amputation) neuroma* and *solitary circumscribed neuroma* (SCN). Traumatic neuromas are complex regenerative proliferations of nerve fibers that follow injury. SCN, formerly known as palisaded encapsulated neuroma, is a benign peripheral nerve sheath tumor whose development is not preceded by apparent tissue injury.

History

The current view of traumatic neuroma was introduced by Huber and Lewis based on the concept of Wallerian degeneration. SCN was described by Reed and co-workers in 1972[4].

Epidemiology

Traumatic neuromas are relatively uncommon but can occur at any age and in either sex. They are more prevalent in professions with a high probability of physical injuries. SCN develops spontaneously and gradually without obvious preceding trauma. These tumors appear during adulthood (mean age, 45 years), and there is no sex predisposition or association with known tumor predisposition syndromes[2–4].

Pathogenesis

The term "neuroma" refers to a benign nerve sheath tumor characterized by a relatively balanced proliferation of Schwann cells and axons, resulting in an axon to Schwann cell ratio close to the normal 1 : 1 ratio[5].

Downloaded for Anonymous User (n/a) at Egyptian Knowledge Bank from ClinicalKey.com by Elsevier on March 10, 2024. For personal use only. No other uses without permission. Copyright ©2024. Elsevier Inc. All rights reserved.

CLASSIFICATION OF CUTANEOUS NEURAL AND NEUROENDOCRINE TUMORS	
Tumors of the peripheral nerve sheath and related structures	**Neural heterotopias**
Neuromas	Meningeal
• Traumatic (amputation) • Solitary circumscribed (palisaded encapsulated) • Multiple mucocutaneous (non-encapsulated) • Epithelial sheath	• Meningocele • Rudimentary meningocele (type 1 meningioma)
	Neuroglial
	• Nasal glial heterotopia ("nasal glioma")
Schwannomas	**Neuroblastic/ganglionic tumors**
• Common • Ancient • Cellular • Plexiform • Epithelioid • Microcystic/reticular • Psammomatous melanotic (malignant melanotic schwannian tumor)	• Primary primitive neuroectodermal tumor • Neuroblastoma • Ganglioneuroma
	Miscellaneous neural and neuroendocrine tumors
Neurofibromas	• Meningioma (type II and type III) • Primary low-grade neuroendocrine carcinoma of the skin (primary cutaneous carcinoid tumor) • Neuroendocrine carcinoma of the skin (Merkel cell carcinoma) • Pigmented neuroectodermal tumor of infancy
• Common (localized cutaneous) • Diffuse • Intraneural (localized) • Plexiform • Ancient (with cytological atypia) • Atypical neurofibromatous neoplasm of uncertain biologic potential (ANNUBP)	
Nerve sheath myxoma* Granular cell tumor Perineurioma • Soft tissue • Sclerosing • Other variants Hybrid peripheral nerve sheath tumor Malignant peripheral nerve sheath tumor	

*Cellular neurothekeoma is now regarded as a distinct entity with no evidence of neural differentiation.

Table 115.1 Classification of cutaneous neural and neuroendocrine tumors.

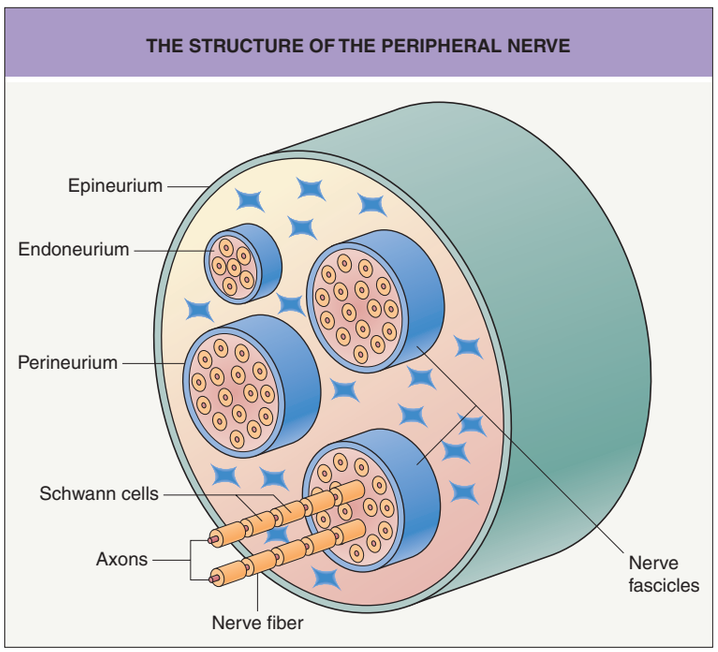

Fig. 115.1 The structure and components of the peripheral nerve.

Fig. 115.2 Traumatic neuroma. A painful, firm papule that appeared after a deep puncture injury.

Traumatic neuromas represent exuberant proliferations of nerve fibers that develop in response to an extrinsic nerve injury. Ideally, a severed nerve is reestablished via an orderly growth of axons and proliferating Schwann cells from the proximal to the distal end of the nerve[6]. If the two nerve ends are not maintained in close apposition, the reparative process fails, resulting in a tangle of irregularly proliferating proximal nerve fascicles embedded within scar tissue.

In SCN there is a coupled proliferation of Schwann cells and axons within the confinement of the perineurium. Its exact pathomechanism remains to be determined. Although a reactive process following minor tissue injury (e.g. facial acne) has been postulated, no definite traumatic origin has been demonstrated[2].

Clinical Features

Traumatic neuromas are usually solitary, skin-colored or reddish purple, firm papules or nodules at sites of wounds, surgical scars, and amputations[7,8] (Fig. 115.2). On the lower extremities, they may be multiple[7]. Early lesions are asymptomatic, but after a few months they gradually become painful, frequently with a lancinating character. Variable tingling and itching can be associated with the pain.

In neonates and young infants, similar lesions may be located on the lateral surface of a normal digit, most commonly the ulnar side of the fifth digit. Such tumors, also referred to as "rudimentary supernumerary digits", have traditionally been regarded as traumatic neuromas secondary to amputation of supernumerary digits *in utero*[9] (see Fig. 64.24). However, on histologic examination, there is no evidence of a pre-existing supernumerary digit, leading some authors to propose that these lesions may represent true congenital malformations.

SCNs present as asymptomatic, rubbery to firm, skin-colored to pink papules or nodules ranging in diameter from 2 to 6 mm[4]. Approximately 90% are located on the face, primarily around the nose, but they also occur on the cheek, chin, lips, and oral mucosa[10]. The remaining 10% occur elsewhere, including the trunk and extremities.

In MEN2B, also referred to as multiple mucosal neuroma syndrome or MEN type 3, numerous soft, skin- or mucosa-colored papules and nodules appear on the eyelid margins, mucosal lips, tongue, and conjunctivae, as well as the nasal and laryngeal mucosae (see Fig. 63.2). Additional findings include pheochromocytomas, medullary carcinoma of the thyroid, gastrointestinal ganglioneuromatosis, rare perinasal cutaneous neuromas, and palpable foci of dermal hyperneury (see Table 63.2). Multiple mucocutaneous neuromas with a predilection for the face and distal extremities may also be a manifestation of the PTEN hamartoma tumor syndrome (see Tables 63.3 & 63.4).

Pathology

Traumatic neuromas are usually well-circumscribed nodules located at any level of the dermis or the subcutis. They are encased by a fibrous sheath, although the distal end can be poorly defined. The proliferation is composed of a chaotic, poorly organized tangle of fascicles of various

Downloaded for Anonymous User (n/a) at Egyptian Knowledge Bank from ClinicalKey.com by Elsevier on March 10, 2024. For personal use only. No other uses without permission. Copyright ©2024. Elsevier Inc. All rights reserved.

CLINICAL FEATURES OF BENIGN NEURAL NEOPLASMS							
	Traumatic (amputation) neuroma	**Solitary circumscribed neuroma (SCN)**	**Schwannoma**	**Neurofibroma**	**Nerve sheath myxoma**	**Cellular neurothekeoma***	**Granular cell tumor**
Incidence	Uncommon	Rare	Uncommon	Very common	Rare	Rare	Rare
Age	Any	Adults (30–60 years)	Adults (30–50 years)	Adults (20–60 years)	Any	Early adulthood (mean age, 24 years)	Adults (30–50 years)
Sex	M:F = 1:1	M:F = 1:1	M:F = 1:1	M:F = 1:1	M:F = 1:1	F:M = 2:1	F>M
Number	Usually solitary	Usually solitary	Usually solitary (>90%)	Usually solitary	Usually solitary	Usually solitary	Usually solitary (10% multiple)
Location	At sites of trauma, surgical scars, amputations	90% face, 10% elsewhere	Flexor aspect of an extremity, head	Trunk, head (solitary type)	Distal extremities	Predominantly on head and upper extremities	25% tongue, 75% elsewhere, mainly head and neck
Size	0.5–2.0 cm	0.2–0.6 cm	0.5–3.0 cm	0.2–2.0 cm	0.5–1.0 cm	0.5–3.0 cm	0.5–3.0 cm
Clinical appearance	Skin-colored to reddish purple, firm papule or nodule	Skin-colored or pink, rubbery to firm papule or nodule	Soft, skin-colored to pink or yellow, smooth-surfaced nodule or tumor	Skin-colored, soft or rubbery papule or nodule, sometimes pedunculated	Soft, skin-colored papule or nodule	Pink, red, or brown, firm papule or nodule	Skin-colored to brownish red, firm papulo-nodule; may have ulcerated or verrucous surface
Symptoms	Variable; tingling, pruritus, lancinating pain	Asymptomatic	Asymptomatic; occasionally painful or tender; rarely paresthesias; occasionally freely movable	Asymptomatic; "buttonhole" sign may be present	Asymptomatic	Usually asymptomatic, rarely painful or pruritic	Asymptomatic or occasionally tender or pruritic
Association	NA	Multiple (non-encapsulated) neuromas in MEN2B (mucosal) and PTEN hamartoma tumor syndrome (mucocutaneous)	Neurofibromatosis type 2, schwannomatosis	If multiple, may be sign of one of the various forms of neurofibromatosis (see Ch. 61)	NA	NA	Multiple tumors more frequently occur in African-Americans and RASopathies (NF1, Noonan syndrome, Noonan syndrome with multiple lentigines)
Clinical differential diagnosis	Hypertrophic scar, dermatofibroma, foreign body granuloma, granular cell tumor, neurothekeoma, phantom limb pain (amputation)	Basal cell carcinoma, adnexal tumor, IDN, neurofibroma, schwannoma, nerve sheath myxoma; when multiple, adnexal tumors (see Fig. 111.5)	Neurofibroma, lipoma, angiolipoma, cyst (epidermoid, pilar, dermoid, ganglion), IDN, adnexal tumors (including sebaceous), SCN, leiomyoma	IDN, soft fibroma, schwannoma, fibrolipoma, SCN, nerve sheath myxoma, anetoderma, lipoma, cyst (epidermoid, pilar)	IDN, neurofibroma, schwannoma, lipoma, cyst (myxoid, ganglion, epidermoid, pilar)	Dermatofibroma (including sclerosing hemangioma variant), adnexal tumor, hypertrophic scar, keloid, granular cell tumor, SCN, fibrosed dermal or compound melanocytic nevus	Tongue: irritation (traumatic) fibroma, verruca, SCC Elsewhere: dermatofibroma, regressing verruca, adnexal tumor, prurigo nodularis, fibrosed melanocytic nevus, SCC
Other	"Rudimentary supernumerary digit" is considered a variant (Ch. 64)		Melanotic schwannoma is a distinct entity and may be associated with Carney complex	Plexiform variant is pathognomonic for NF1		Gene expression profile suggests fibrohistiocytic differentiation	Visceral forms occur; true malignant transformation rare

*Cellular neurothekeoma is no longer considered to be a neural neoplasm.

Table 115.2 Clinical features of benign neural neoplasms. NA, not applicable; IDN, intradermal melanocytic nevus; MEN2B, multiple endocrine neoplasia, type 2B; NF1, neurofibromatosis type 1; SCC, squamous cell carcinoma.

sizes and shapes (Fig. 115.3). Between the fibers are variable amounts of fibrous tissue with or without inflammatory cells and mucin[5]. The constituent cells are Schwann cells and accompanying perineurial cells with spindle-shaped nuclei and cytoplasm. Special stains show several axons in an irregular, haphazard pattern[1,2].

SCNs present as well-circumscribed, ovoid or round nodules within the mid dermis, although some lesions may extend into the subcutis; occasionally, there is a multinodular, plexiform growth pattern. The tumor appears at least partially encapsulated by a thin connective tissue sheath composed of perineurial cells[10] (Fig. 115.4). The parenchyma consists of interwoven fascicles of spindled cells. Fascicles are compactly and relatively uniformly arranged, occasionally separated by clefts. The stroma is relatively monomorphous, and in contrast to traumatic neuromas, there is no evidence of inflammation, granulation tissue, or scarring[5].

Downloaded for Anonymous User (n/a) at Egyptian Knowledge Bank from ClinicalKey.com by Elsevier on March 10, 2024. For personal use only. No other uses without permission. Copyright ©2024. Elsevier Inc. All rights reserved.

HISTOLOGIC DIFFERENTIAL DIAGNOSTIC FEATURES OF COMMON CUTANEOUS NEURAL NEOPLASMS				
	Traumatic neuroma	**Solitary circumscribed neuroma**	**Schwannoma**	**Neurofibroma (localized cutaneous variant)**
Location in the skin	Any level of dermis or subcutis	Mid dermis, occasionally extending into subcutis	Deep dermis or subcutis	Any location in the dermis
Growth pattern	Usually well circumscribed but may be poorly defined at the distal end	Well circumscribed, nodular, rarely plexiform	Well circumscribed, nodular or ovoid	Poorly to well circumscribed
Encapsulation	Usually encased by a fibrous sheath	Yes, by perineurium	Yes, by perineurium	Not encapsulated in the dermis
Architecture	Chaotic, poorly organized tangle of fascicles of various sizes and shapes	Compactly arranged fascicles; frequent clefts between fascicles	Hypercellular areas (Antoni A), fascicles in various patterns, hypocellular areas (Antoni B), edematous, myxoid	Fine fibrillary lattice of haphazardly arranged spindle cells in variably dense matrix
Constituent cell types	Schwann cells, perineurial cells, fibroblasts, mast cells, macrophages	Schwann cells (99%), perineurial cells (in capsule only)	Schwann cells (99%), perineurial cells (in capsule only)	Schwann cells, perineurial cells, fibroblasts, mast cells
Cytologic features	Spindle cells with indistinct cytoplasmic contours and tapered slender nuclei	Spindle cells with indistinct cytoplasmic contours and tapered slender nuclei	Spindle cells with indistinct cytoplasmic contours and slender nuclei	Spindle cells with slender nuclei, plump fibroblasts
Nuclear palisading	None	Usually present, but indistinct	Yes (Antoni A areas)	Rarely
Verocay bodies	None	None	Often	None
Nerve fibers (axons)	Yes; abundant, irregular pattern	Yes; abundant, often in a parallel arrangement	Yes; very rare, more frequent at the site of the connecting nerve	Yes; rare, scattered
Other important features	Nerve of origin frequently present, extensive fibrosis	Nerve of origin frequently present, no fibrosis	Mast cells; may have extensive degenerative changes (e.g. hyalinization, hemorrhage) in Antoni B areas ("ancient changes")	Variable fibrosis and myxoid changes, mast cells, occasional blood vessels
Histopathologic differential diagnosis	Hypertrophic scar, neurofibroma, schwannoma, palisaded encapsulated neuroma	Traumatic neuroma, schwannoma, angioleiomyoma, myofibroma	Palisaded encapsulated neuroma, angiomyoma, fibrous histiocytoma, traumatic neuroma	Melanocytic nevus with neuroid differentiation, dermatofibroma, hypertrophic scar, dermatofibrosarcoma protuberans, traumatic neuroma

Table 115.3 Histologic differential diagnostic features of common cutaneous neural neoplasms.

IMMUNOHISTOCHEMICAL STAINING OF CUTANEOUS NEURAL NEOPLASMS AND THE MAJOR TUMORS IN THE DIFFERENTIAL DIAGNOSIS							
Neoplasm	**Immunohistochemical stain**						
	NF (for axons)	**S100**	**SOX10**	**EMA***	**CD34**	**Melan-A**	**SMA**
Traumatic neuroma	+	+	+	±	–	–	–
Solitary circumscribed neuroma	+	+	+	+ (peripheral capsule)	–	–	–
Schwannoma and variants	–†	+	+	+ (peripheral capsule)	–	–^	–
Neurofibroma and variants‡	±	+	+	±	±	–	–
Nerve sheath mixoma	–†	+	+	± (peripheral capsule)	±	–	–
Cellular neurothekeoma	–	–	–	–	–	–	±
Perineurioma	–	–	–	+ (neoplastic cells)	±	–	–
Granular cell tumor	–	+	+	–	–	–	–
Malignant peripheral nerve sheath tumor¶	±	±	±	–	–	–	–
Melanocytic nevus with neural differentiation	–	+	+	–	–	+	–
Dermatofibrosarcoma protuberans	–	–^^	–	–	+	–	–
Leiomyoma	–	–	–	–	–	–	+

*Similar pattern of immunoreactivity may be observed with GLUT1 and claudin-1
†Very sparse axons may be demonstrated in serial immunostained sections
‡In some variants, staining pattern may be variable
¶The rare perineurial variant is S100(–) / SOX10(–) / EMA(+)
^Positive in psammomatous melanotic schwannomas.
^^In the pigmented variant (Bednar tumor), scattered S100-/SOX10-/Melan-A-positive dendritic melanocytes are seen but the neoplastic cells are negative.

Table 115.4 Immunohistochemical staining of cutaneous neural neoplasms and the major tumors in the differential diagnosis. EMA, epithelial membrane antigen; Melan-A, melanocyte-related antigen; NF, neurofilament; S100, S100 protein; SMA, smooth muscle actin. +, positive; –, negative.

Downloaded for Anonymous User (n/a) at Egyptian Knowledge Bank from ClinicalKey.com by Elsevier on March 10, 2024. For personal use only. No other uses without permission. Copyright ©2024. Elsevier Inc. All rights reserved.

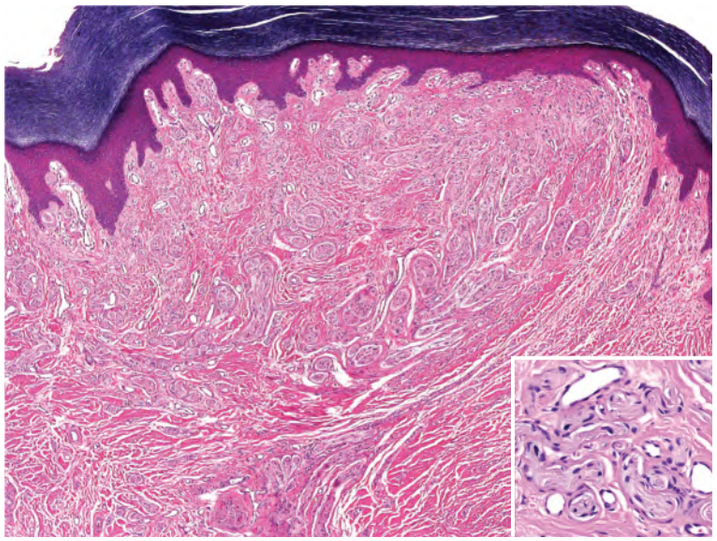

Fig. 115.3 Traumatic neuroma. Acral lesion with a chaotic proliferation of nerve fascicles is embedded in a fibrous stroma. Note nerve fascicles within a fibrotic stroma (inset). *Courtesy Lorenzo Cerroni, MD.*

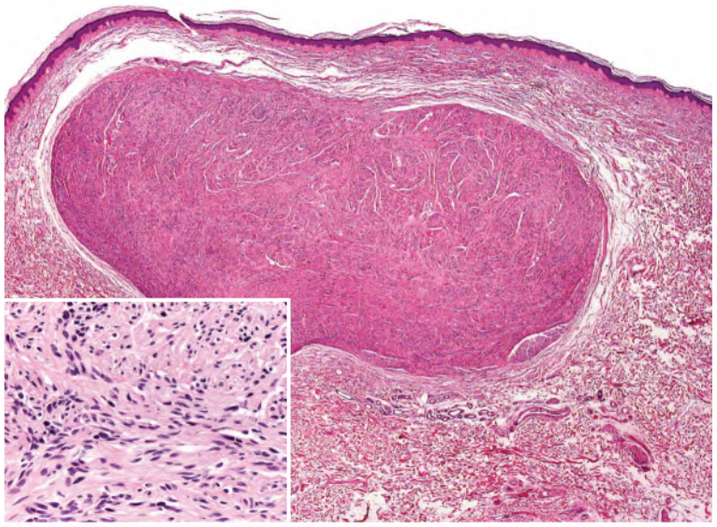

Fig. 115.4 Solitary circumscribed neuroma. The well-circumscribed dermal nodule appears encapsulated. Note nerve fascicles (inset). *Courtesy Lorenzo Cerroni, MD.*

The nuclei of the spindle-shaped tumor cells are elongated and wavy with tapered ends and an evenly basophilic chromatin pattern. Occasionally, a parallel arrangement of the nuclei is present, but distinct palisading or Verocay body formation is unusual[11–13]. No appreciable nuclear pleomorphism or mitotic activity is observed. In contrast to schwannomas, abundant axons throughout the tumor nodules may be highlighted via special stains[11] (Fig. 115.5).

Mucosal neuromas in MEN2B consist of non-encapsulated, tortuous proliferations of nerve bundles with a prominent perineurium, while dermal hyperneury is characterized by an increased number of enlarged and haphazardly arranged dermal nerves. Epithelial sheath neuroma represents a more recently described entity in which there is hyperplasia of mature nerve fascicles within the dermis (akin to dermal hyperneury), but each fascicle is surrounded by an aberrant sheath of squamous epithelium instead of normal perineurium; these features must be distinguished from perineural invasion by malignant tumors[14].

Differential Diagnosis

The diagnosis of traumatic neuroma is usually suspected by the history of a painful or symptomatic papulonodule at a site of injury and is confirmed by pathologic examination. Clinically, SCNs may resemble a BCC, adnexal tumor, intradermal melanocytic nevus, or neurofibroma (see Table 115.2). The diagnosis usually depends upon histologic examination (see Table 115.3).

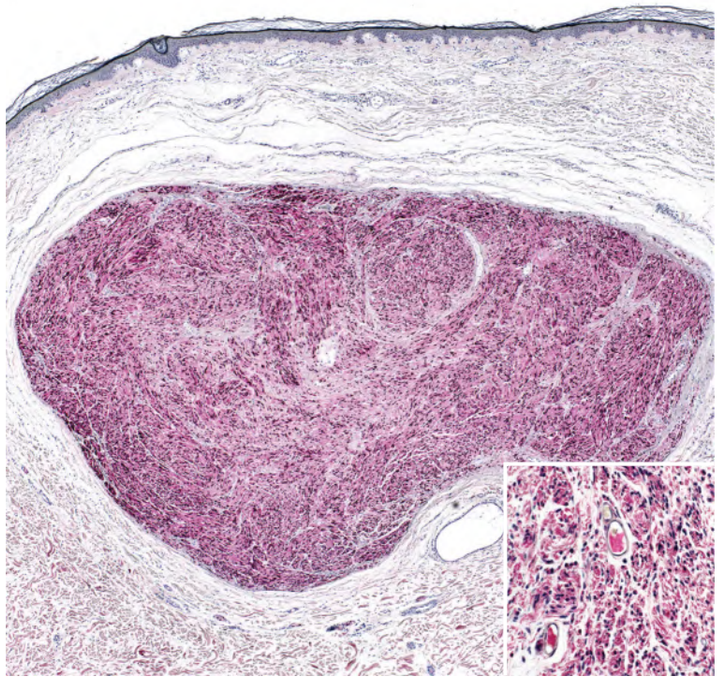

Fig. 115.5 Solitary circumscribed neuroma. Diffuse positivity for S100 within the dermal nodule. Note expression of S100 by the nerve fascicles (inset). *Courtesy Lorenzo Cerroni, MD.*

Treatment

Surgical excision of traumatic neuromas is recommended, with an attempt to reposition the proximal nerve stump into a scar-free area[7]. SCNs are easily excised, and some can even be enucleated from the surrounding dermis or subcutaneous tissue[4].

SCHWANNOMA

Synonyms: ▪ Neurilemmoma ▪ Neurolemmoma ▪ Schwann cell tumor ▪ Acoustic neuroma

Key features

- Solitary papulonodule that usually appears on the flexural aspect of an extremity, along a peripheral nerve
- Occasionally painful or tender
- Deep dermal or subcutaneous location
- Histologically, there is an encapsulated spindle cell proliferation with biphasic Antoni A and B areas, palisading of nuclei, and Verocay bodies; rare axons are present

Introduction

Schwannomas are benign encapsulated nerve sheath neoplasms nearly entirely composed of differentiated Schwann cells.

History

Stout coined the term "neurilemoma", referring to the closely applied sheath and covering of the tumor[15]. Because nearly the entire tumor is composed of Schwann cells, the designation "schwannoma" is preferred.

Downloaded for Anonymous User (n/a) at Egyptian Knowledge Bank from ClinicalKey.com by Elsevier on March 10, 2024. For personal use only. No other uses without permission. Copyright ©2024. Elsevier Inc. All rights reserved.

Epidemiology

Schwannomas may occur at any age, with a peak incidence during the fourth to sixth decades of life. There is no sex or racial predilection. Approximately 90% of schwannomas are solitary and occur sporadically[2]. Multiple schwannomas can be a manifestation of neurofibromatosis type 2 (NF2) or schwannomatosis, with both disorders having a mosaic (segmental) form. Patients with NF2, an autosomal dominant disorder, can develop meningiomas and bilateral vestibular schwannomas ("acoustic neuromas") (see Table 61.5)[2,16–19]. The latter tumors are unusual in schwannomatosis which is sporadic in the majority of patients (see below).

Psammomatous melanotic schwannoma (also more recently referred to as "malignant melanotic schwannian tumor") is a variant that typically arises from spinal and autonomic nerves[20]. This tumor may occur sporadically as well as in the setting of Carney complex (see Ch. 112). *Primary cutaneous* psammomatous melanotic schwannomas are exceedingly rare and appear to have a more indolent behavior than extracutaneous counterparts.

Pathogenesis

Because a schwannoma is a neoplastic proliferation of periaxonal or endoneurial Schwann cells, it develops as an encapsulated mass within the confines of the perineurium. Normal nerve fascicles are passively displaced to the periphery, with the bulk of the tumor appearing devoid of other normal peripheral nerve components[2]. Only after careful dissection can the attached nerve trunk be demonstrated.

Loss of expression of merlin, the oncosuppressor protein encoded by *NF2*[21,22], leads to the development of schwannomas. *Somatic* inactivating mutations in *NF2* occur in 50%–75% of sporadic schwannomas, while *germline* inactivating mutations lead to NF2. Both inherited and sporadic (~40% of patients) schwannomatosis are associated with germline mutations in either *SMARCB1* or *LZTR1*, coupled with somatic biallelic inactivation of *NF2* in each tumor[17–19]. The development of psammomatous melanotic schwannomas, either sporadically or in association with Carney complex, is related to inactivation of *PRKAR1A*.

Clinical Features

Schwannomas present as solitary, soft, skin-colored to pink or yellow, smooth-surfaced, dermal or subcutaneous papulonodules (Fig. 115.6). In general, their diameter ranges between 0.5 and 3 cm[23]. They are most commonly found on the flexor aspect of extremities along a larger nerve trunk, followed by the head and neck region[24]. Tumors are usually asymptomatic, but occasionally pain and tenderness occur, in particular if forceful movements place the attached nerve under tension. Motor disturbances and paresthesias are extremely rare[25].

Pathology

Schwannomas are well-circumscribed, nodular or ovoid tumors composed of differentiated Schwann cells. They are located in the deep dermis or subcutis and are almost always encapsulated. The tumors are composed of hypercellular (also called Antoni A-type tissue) and hypocellular (Antoni B-type tissue) areas[2]. Within areas of Antoni A-type tissue, there is proliferation of spindle cells with indistinct cytoplasmic contours and uniform nuclei[26]. Nuclear palisading is a typical finding and palisaded nuclei arranged in double rows can result in characteristic "Verocay bodies"[2,3] (Fig. 115.7). Mitotic figures are absent or rare.

Antoni B-type tissue areas have characteristic large, irregularly spaced vessels with thickened fibrotic walls, as well as variable degrees of edematous, mucinous, cystic, xanthomatous, and fibrotic changes within the hypocellular stroma. Such degenerative changes, which are often associated with some degree of cytologic atypia, are the predominant feature in so-called *ancient schwannomas*. These latter tumors should not be confused with *cellular schwannomas*, a histologic subtype composed largely of Antoni A-type tissue but lacking Verocay bodies, that rarely occur in the skin[27]. Axons are sparse in schwannomas and may be best detected at the tumor's periphery in proximity to nerve attachments[28].

Additional less common subtypes of schwannomas include plexiform, epithelioid (frequently associated with loss of SMARCB1 expression), and microcystic/reticular schwannomas[29–31]. In psammomatous melanotic schwannoma, a mixture of spindled and epithelioid cells that resembles syncytial tissue is seen. The cells have variable pleomorphism and nuclear atypia, and focal areas may demonstrate typical neural organization, i.e. nuclear palisading and whorl formation. Melanin deposition is often heavy, obscuring cytologic details. Psammomatous structures, consisting of eosinophilic laminated and whorled structures with variable calcification, are a frequent and characteristic finding. The cells stain positively for S100 protein and SOX10 and in psammomatous melanotic schwannomas also stain positively for Melan-A, HMB-45, and tyrosinase[32].

Differential Diagnosis

The clinical differential diagnosis includes neurofibroma, lipoma, angiolipoma, adnexal tumor, cyst (epidermoid, pilar, dermoid, ganglion), and intradermal melanocytic nevus. The diagnosis is made by histopathologic examination. Clinically, a psammomatous melanocytic schwannoma may resemble a blue, combined, or atypical melanocytic nevus.

Fig. 115.6 Solitary cutaneous schwannoma. Skin-colored nodule on the plantar surface of the great toe. *Courtesy Julie V. Schaffer, MD.*

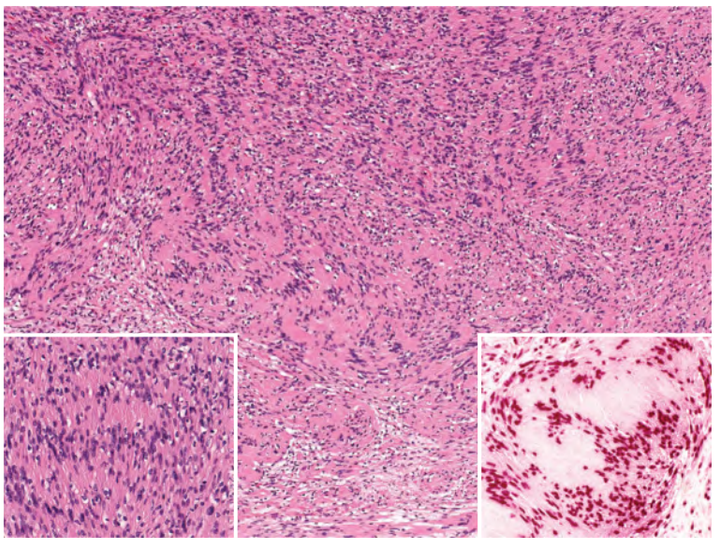

Fig. 115.7 Solitary cutaneous schwannoma. Hypercellular areas often show nuclear palisading and Verocay bodies. Detail of Verocay bodies and the nuclear expression of SOX10 (insets). *Courtesy Lorenzo Cerroni, MD.*

Downloaded for Anonymous User (n/a) at Egyptian Knowledge Bank from ClinicalKey.com by Elsevier on March 10, 2024. For personal use only. No other uses without permission. Copyright ©2024. Elsevier Inc. All rights reserved.

Treatment

Schwannomas are benign and a simple excision is curative. If the clinical diagnosis is suspected, the tumor should be removed by enucleation, preserving normal nerve function.

NEUROFIBROMA

Variants/synonyms: ■ Solitary neurofibroma – sporadic neurofibroma, solitary nerve sheath tumor ■ Plexiform neurofibroma

Key features

Solitary type

- Skin-colored to tan–violet papule or nodule
- May be pedunculated or have the "buttonhole" sign
- Predilection for the trunk and head
- Spindle cell proliferation with variable mixture of the components of the peripheral nerve, including residual axons
- Fibrosis and mucinous changes are common

Plexiform type

- Pathognomonic of NF1
- Large, occasionally pigmented, bag-like mass
- Favors the trunk and proximal extremities
- The plexiform variant has similar cytologic constituents as the solitary or sporadic type, but carries a risk of malignant transformation

Introduction

Neurofibromas are benign nerve sheath tumors composed of a complex proliferation of neuromesenchymal cells (Schwann cells, perineurial cells, fibroblasts, and mast cells), along with residual interspersed axons[2]. Cutaneous neurofibromas are common, especially as solitary lesions. The presence of multiple neurofibromas raises the possibility of one of the several types of neurofibromatosis, including the mosaic form (see Ch. 61). Plexiform neurofibromas are pathognomonic of NF1.

History

Neurofibromas were originally described as fibrous tumors by von Recklinghausen. A neuroectodermal origin was suggested by Verocay and eventually confirmed by immunohistochemical and ultrastructural studies.

Epidemiology

Localized cutaneous neurofibromas are the most common peripheral nerve sheath tumors, and have neither age nor sex preference. Diffuse and plexiform neurofibromas are considered to be of congenital origin.

Pathogenesis

Neurofibromas differ from schwannomas in that several cell types are involved in their histogenesis. Regardless of the histologic subtype of neurofibromas (e.g. localized cutaneous, diffuse, plexiform), the basic process is proliferation of the entire "neuromesenchyme", which includes Schwann cells, perineurial cells, endoneurial fibroblasts, and mast cells[2]. Axons are easily found in neurofibromas, although the axon to Schwann cell ratio is significantly lower than the normal 1 : 1 ratio. Within a neurofibroma, only a subpopulation of Schwann cells is neoplastic, carrying a clonal biallelic inactivation of *NF1*. Nullizygosity ($NF1^{-/-}$) of Schwann cells is a prerequisite, but is not sufficient, for neurofibroma formation; the latter may require the promoting effect of a $NF1^{+/-}$ microenvironment, in particular *NF1*-haploinsufficient mast cells[33] (see Fig. 61.2). The pathogenesis of sporadic cutaneous neurofibromas remains unclear, as most of them show retained expression of neurofibromin[34].

Clinical Features

Clinically, *localized cutaneous* neurofibromas present as asymptomatic, skin-colored, soft or rubbery papulonodules. They range in size from 0.2 to 2 cm and may become pedunculated[2]. These tumors grow slowly and the "buttonhole" sign is often present[2], i.e. the tumor is easily invaginated. Approximately 10% of patients develop multiple localized cutaneous neurofibromas, with some of these patients having one of the several types of neurofibromatosis (see Ch. 61). Additional clinicopathologic subtypes of neurofibroma include diffuse, intraneural, and plexiform variants. The diffuse subtype may present as indurated or soft nodules and plaques, while the intraneural variant presents as solitary fusiform masses. Except for plexiform neurofibromas, these subtypes rarely undergo malignant change.

Plexiform neurofibromas are especially important because they are considered pathognomonic of NF1 and carry a significant risk of transformation into malignant peripheral nerve sheath tumors (MPNSTs)[2]. These neurofibromas affect large segments of a nerve, distorting it into a "bag of worms", and present as baggy or pedunculated subcutaneous masses that can feel rope-like on palpation and are frequently hyperpigmented (Fig. 115.8). Involvement of an entire extremity leads to elephantiasis neuromatosa. Recognition and correct patient management is crucial in these cases, especially in subtle forms of NF1, where the other cutaneous stigmata may not be obvious. The exact incidence of malignant transformation is not known but it is estimated to occur in 2%–30% of NF1 patients, depending on disease severity in the population studied[2].

Pathology

Neurofibromas are poor- to well-circumscribed, nodular or oblong tumors that can be located anywhere within the dermis and subcutis[2,3]. Even when localized grossly, they lack a capsule and tend to infiltrate surrounding soft tissues. The common *localized cutaneous* variant usually has its center in the superficial dermis, creating a dome-shaped or polypoid elevation of its surface (Fig. 115.9). The tumor is composed of a fine fibrillary lattice of haphazardly arranged slender spindle cells[35], and the stroma can be variably vascular, fibrotic, edematous or myxomatous. In addition to Schwann cells and perineurial cells, plump fibroblasts and mast cells are present. Vague palisading of nuclei may occur, occasionally with true Verocay body formation, and can be regarded as hybrid neurofibroma/schwannoma tumors[2,35]. Mitotic figures are absent or rare. By utilizing special stains, rare scattered axons may be demonstrated, as in all other variants.

The *diffuse* variant lacks a well-defined growth pattern as it infiltrates the dermis and subcutis; characteristically, Meissner body-like structures may be observed in the deeper parts of these tumors. Intraneural neurofibromas are well-circumscribed masses along a peripheral nerve, being encapsulated by perineurium or epineurium[2]. *Plexiform* neurofibromas consist of a tortuous mass of neurofibromatous tissue with

Fig. 115.8 Plexiform neurofibroma in a patient with neurofibromatosis type 1. Soft, pendulous mass with "bag of worms" appearance. *Courtesy Lorenzo Cerroni, MD.*

Downloaded for Anonymous User (n/a) at Egyptian Knowledge Bank from ClinicalKey.com by Elsevier on March 10, 2024. For personal use only. No other uses without permission. Copyright ©2024. Elsevier Inc. All rights reserved.

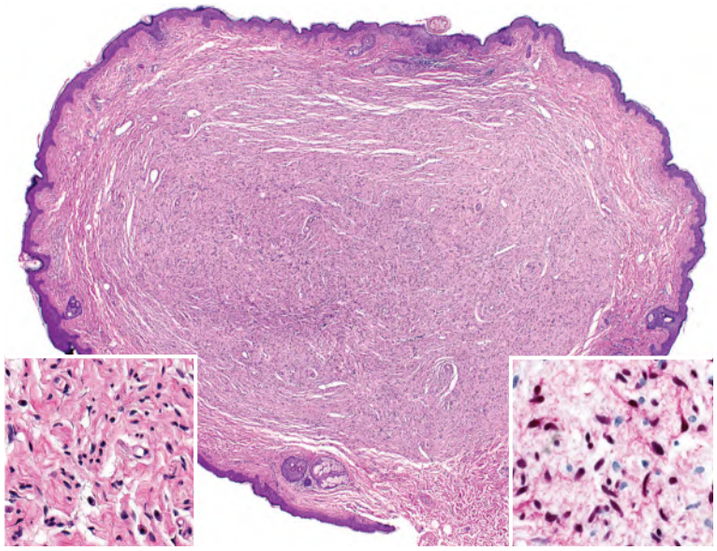

Fig. 115.9 Neurofibroma. Unencapsulated dermal proliferation of spindle cells separated from the overlying epidermis by a grenz zone. The tumor contains a diffuse proliferation of spindle cells with slender, ovoid nuclei in a mast cell-rich fibrillary matrix (inset lower left). Note expression of S100 by spindle cells (inset lower right). *Courtesy Lorenzo Cerroni, MD.*

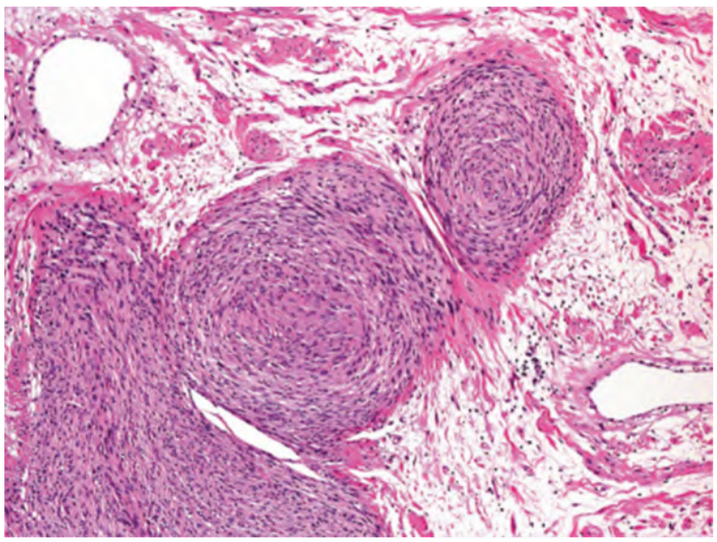

Fig. 115.10 Plexiform neurofibroma. Irregularly expanded, twisted fascicles of neoplastic cells arranged in lobular structures. *Courtesy Lorenzo Cerroni, MD.*

an intraneural origin (Fig. 115.10). The neoplastic tissue progressively expands within the nerve branch then extends into the surrounding soft tissue, resulting in the frequent combination of intraneural and diffuse extraneural growth patterns.

MPNSTs may develop from pre-existing plexiform neurofibromas via deletions of the *CDKN2A/CDKN2B* locus. While cytological atypia alone in neurofibromas is not worrisome ("ancient neurofibromas"), malignant transformation is heralded by an intermediate histopathologic step (so-called "atypical neurofibromatous neoplasm of uncertain biologic potential" [ANNUBP]), which is defined by a variable combination of nuclear atypia, increased cellularity, and increased mitotic activity[36].

Differential Diagnosis

The clinical differential diagnosis of a solitary neurofibroma includes an intradermal melanocytic nevus, schwannoma, soft fibroma, and fibrolipoma (see Table 115.2). The majority of solitary or sporadic neurofibromas have similar clinical and histologic features to the multiple papular neurofibromas seen in patients with NF1. Plexiform neurofibromas with overlying hyperpigmentation and hypertrichosis can resemble congenital melanocytic nevi. As the latter can undergo neurotization and may be accompanied by satellite lesions, examination of the patient for Lisch nodules, axillary freckling, and café-au-lait macules is essential. Histologically, a plexiform neurofibroma must be differentiated from other plexiform tumors, including plexiform schwannoma, plexiform SCN, and desmoplastic melanoma.

Treatment

Neurofibromas are usually treated by simple excision. The evaluation and management of plexiform neurofibromas and neurofibromatosis is discussed in Chapter 61.

NERVE SHEATH MYXOMA AND CELLULAR NEUROTHEKEOMA

Synonyms: ■ Myxoma of the nerve sheath ■ Neurothekeoma

Key features

- Two distinct entities previously classified as morphologic variants within the same spectrum
- Nerve sheath myxoma is a true benign nerve sheath tumor with schwannian differentiation
- Cellular neurothekeoma is a non-neural neoplasm of presumptive fibrohistiocytic differentiation
- Both tumors present as nonspecific skin-colored to red–brown papulonodules
- Histologically, both tumors have a lobular or fascicular pattern with variable deposition of extracellular mucin
- Benign behavior, but local recurrences may occur

Introduction

Classic (myxoid) nerve sheath myxoma and cellular neurothekeoma were initially regarded as subtypes of the same neuromesenchymal entity ("nerve sheath myxoma"), characterized by the proliferation of nerve sheath cells in a variably myxomatous stroma[37]. There is now sufficient evidence to state that cellular neurothekeoma is not related to nerve sheath myxoma or to the neural crest, but rather represents a non-neural mesenchymal neoplasm, perhaps of fibrohistiocytic differentiation[38]. As such, the term "neurothekeoma" is a misnomer.

History

Nerve sheath myxoma was first described as a specific entity by Harkin and Reed in 1969. The term "cellular neurothekeoma" was coined by Rosati and colleagues in 1986[2].

Epidemiology

True nerve sheath myxomas are rare, affecting all ages and both sexes equally[39]. Cellular neurothekeoma has a predilection for adolescents and young adults (<40 years of age) and is nearly twice as common in women as men[40].

Pathogenesis

True *nerve sheath myxomas* are superficial peripheral nerve sheath tumors characterized by a benign proliferation of schwannian cells in a plexiform/multinodular growth pattern plus abundant myxoid degeneration. A thin, incomplete layer of perineurial cells may surround the nodules, as in SCN[39,41]. The extreme mucin production may explain the difficulty in detecting axons in these tumors.

Cellular neurothekeoma has a controversial histogenesis. Despite its morphologic similarities to nerve sheath myxoma, there is no expression of schwannian differentiation markers (e.g. S100 protein, SOX10)[40,42]. Based upon gene expression profile analyses, cellular neurothekeoma is more closely related to fibrohistiocytic neoplasms[38].

Downloaded for Anonymous User (n/a) at Egyptian Knowledge Bank from ClinicalKey.com by Elsevier on March 10, 2024. For personal use only. No other uses without permission. Copyright ©2024. Elsevier Inc. All rights reserved.

Fig. 115.11 Cellular neurothekeoma of the scalp, presenting as a small, firm, erythematous nodule.

Clinical Features

Nerve sheath myxoma is a soft, skin-colored papule or nodule, generally 5 to 10 mm in diameter and typically located on the distal extremities[39].

Cellular neurothekeomas favor the head and neck region as well as the upper extremities, although cases from a variety of anatomic sites have been reported. These tumors are described as firm papulonodules that are pink, red, or brown in color and range in size from 0.5 to 3 cm (Fig. 115.11). Symptoms are nonspecific and seem to relate to the size and firmness of the tumor[40].

Pathology

Nerve sheath myxoma is a well-defined, lobular or plexiform neoplasm that is usually located in the reticular dermis (Fig. 115.12). It often appears encapsulated by a compression of the surrounding fibrous tissue[39]. There is a hypocellular myxoid stroma with rare scattered spindled, stellate, or dendritic cells. The cells usually have scant pale cytoplasm with indistinct cytoplasmic contours and hyperchromatic, ovoid, or angulated nuclei[39,41]. Nucleoli are small and mitotic figures are rare or absent. On occasion, multinucleated giant cells with eosinophilic cytoplasm can be identified. Histochemically, the myxoid stroma stains strongly positive for acidic mucopolysaccharides (see Ch. 46)[39]. In a minority of cases, scattered neurofilament-positive axons may be detected[41]. The tumor cells are positive for S100 protein, SOX10, and collagen type IV and the capsule has a weak and discontinuous expression of epithelial membrane antigen (EMA) and other perineurial markers[2,41].

Cellular neurothekeomas are composed of ill-defined multilobular masses or fascicles in the reticular dermis[40] (Fig. 115.13). In some cases, the growth pattern can be frankly infiltrative or dissecting without any hint of a residual capsule, and there may be involvement of the superficial subcutis[42,43]. Cytologically, the predominant cell types are epithelioid or polygonal cells with ample eosinophilic cytoplasm and round nuclei with an open chromatin pattern[40,43]. Many cells have prominent nucleoli. Less often, the constituent cells are spindle-shaped with hyperchromatic nuclei, resembling those observed in nerve sheath myxomas. Mitotic figures are often present but are usually normal morphologically. Rare cases with increased mitotic figures and cytologic atypia have been reported[43]. The stroma can be markedly fibrotic or even hyalinized. There is no detectable connection with peripheral nerves.

The tumor does not have a consistent immunohistochemical profile, with the nonspecific marker NKI/C3 expressed in essentially all cases. Expression of PGP9.5 (neuron-specific peptide), microphthalmia transcription factor (MITF; see Ch. 65), and smooth muscle actin may be observed in individual cases. Importantly, expression of S100 protein, SOX10, and perineurial markers is consistently absent[40,44,45].

Differential Diagnosis

A nerve sheath myxoma is usually asymptomatic and clinically is often mistaken for an intradermal melanocytic nevus, neurofibroma, lipoma, or cyst (e.g. myxoid, ganglion) (see Table 115.2). Clinically, a cellular neurothekeoma usually resembles a dermatofibroma (including the sclerosing hemangioma variant), hypertrophic scar, keloid, or granular cell tumor.

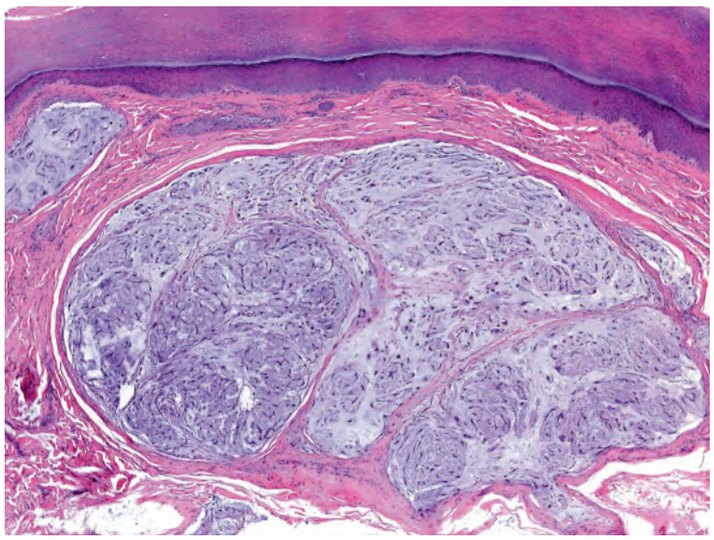

Fig. 115.12 Nerve sheath myxoma. Well-defined fascicles with myxoid stroma. *Courtesy Lorenzo Cerroni, MD.*

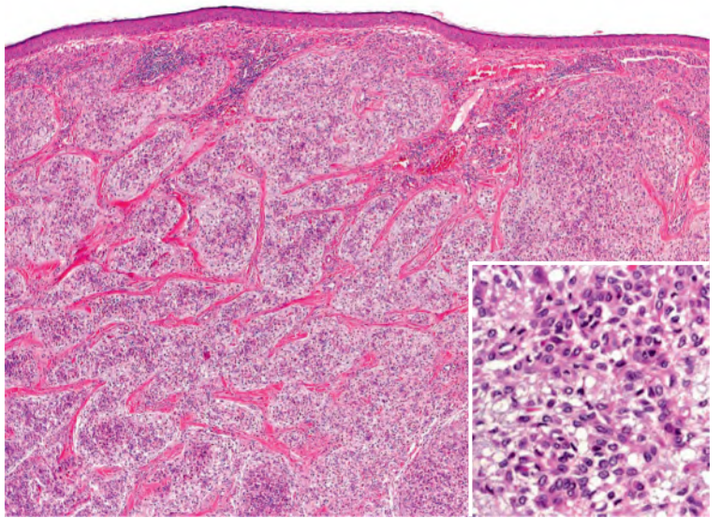

Fig. 115.13 Cellular neurothekeoma. Epithelioid nests are dispersed in a hyalinized stroma. Whorl-like arrangement of epithelioid cells with nuclear pleomorphism (inset). *Courtesy Lorenzo Cerroni, MD.*

Treatment

These lesions are usually treated by simple excision; however, if incompletely removed, a nerve sheath myxoma may recur. There have been a few case reports of atypical variants of cellular neurothekeoma with postulated uncertain behavior, in which case complete excision is recommended.

GRANULAR CELL TUMOR

Synonym: ▪ Abrikossoff's tumor

Key features

- Seen more commonly in adults, women, and African-Americans
- Predilection for the head and neck, tongue, and breast, but may occur anywhere, including the viscera
- Malignant transformation is rare and usually occurs with deep-seated lesions
- Histologically, an ill-defined, infiltrative tumor, often with associated pseudoepitheliomatous (pseudocarcinomatous) hyperplasia
- Large polygonal cells with finely granular eosinophilic cytoplasm; the granules are PAS-positive, diastase-resistant

Downloaded for Anonymous User (n/a) at Egyptian Knowledge Bank from ClinicalKey.com by Elsevier on March 10, 2024. For personal use only. No other uses without permission. Copyright ©2024. Elsevier Inc. All rights reserved.

Introduction

Granular cell tumor is a neoplasm with neuroectodermal differentiation consisting of epithelioid to polygonal cells with granular change due to cytoplasmic accumulation of lysosomal granules. The exceedingly rare "cutaneous non-neural granular cell tumor" is a morphologically indistinguishable neoplasm that lacks expression of S100 protein or SOX10 and has frequent *ALK* (anaplastic lymphoma kinase gene) rearrangements[46]. Occasionally, granular cell change may occur in a variety of unrelated neoplasms as a secondary phenomenon (see below)[47].

History

This tumor was originally thought by Abrikossoff, who used the term "granular cell myoblastoma", to be derived from muscle[48]. Feyrter first suggested a neural origin.

Epidemiology

Granular cell tumor is a relatively rare tumor that occurs primarily in adults (age 30–50 years) and favors men and African-Americans. Up to 10% of patients have multiple lesions, and ~70% of tumors are located in the head and neck region, including 25% on the tongue[2]. Other common locations are the breast (5%–15%) and proximal extremities. Visceral lesions may develop in the gastrointestinal and upper respiratory tracts.

Pathogenesis

The neural origin of granular cell tumor has been a subject of debate, but immunohistochemical and ultrastructural studies have clearly proven its schwannian differentiation. Granular cells express S100 protein, SOX10, and CD57 (a neuronally expressed adhesion molecule), like Schwann cells[49–51]. Loss-of-function mutations in the V-ATPase accessory genes *ATP6AP1* (60%) and *ATP6AP2* (10%) have been detected in the majority of cutaneous and extracutaneous neural granular cell tumors, irrespective of anatomic site and biological behavior[52,53]. How inactivation of these membrane proton pumps leads to accumulation of lysosomes and tumorigenesis requires further investigation. Multiple cutaneous granular cell tumors can be seen in patients with RASopathies such as NF1, Noonan syndrome, and Noonan syndrome with multiple lentigines (LEOPARD syndrome), thus implying a role of the RAS/MAPK pathway in their pathogenesis[54] (see Fig. 55.4).

Clinical Features

A granular cell tumor presents as an asymptomatic or occasionally tender or pruritic, skin-colored to brownish-red, firm dermal or subcutaneous papulonodule, ranging in diameter from 0.5 to 3 cm. Occasionally, the surface will be ulcerated or verrucous. Granular cell tumors are slowly growing and in general have a benign behavior. Rarely, malignant behavior is observed (local infiltration or metastasis), more often when the tumor arises from a visceral or deep location. Malignant granular tumors may develop *de novo* or via malignant transformation of a pre-existing benign lesion[55].

Pathology

The dermis contains a poorly circumscribed nodule composed of polygonal, pale-staining cells that may infiltrate into the adjacent subcutis. The cells have abundant, granular, faintly eosinophilic cytoplasm with round, dark nuclei (Fig. 115.14)[56]. Characteristic larger cytoplasmic granules are called pustulo-ovoid bodies. With the PAS reaction, the granules are positive, but they are diastase-resistant. Occasionally, a perineurial growth pattern is present; however, the tumor is devoid of axons. Increased numbers of mast cells are present in some lesions, and the overlying epidermis is frequently hyperplastic. Rarely, a plexiform growth pattern has been described[56]. Histopathologic criteria predictive of aggressive behavior are not well established, but may include necrosis, increased mitotic rate, spindling of the cells, high nuclear:cytoplasmic ratio, vesicular nuclei, and nuclear pleomorphism[2,55,57].

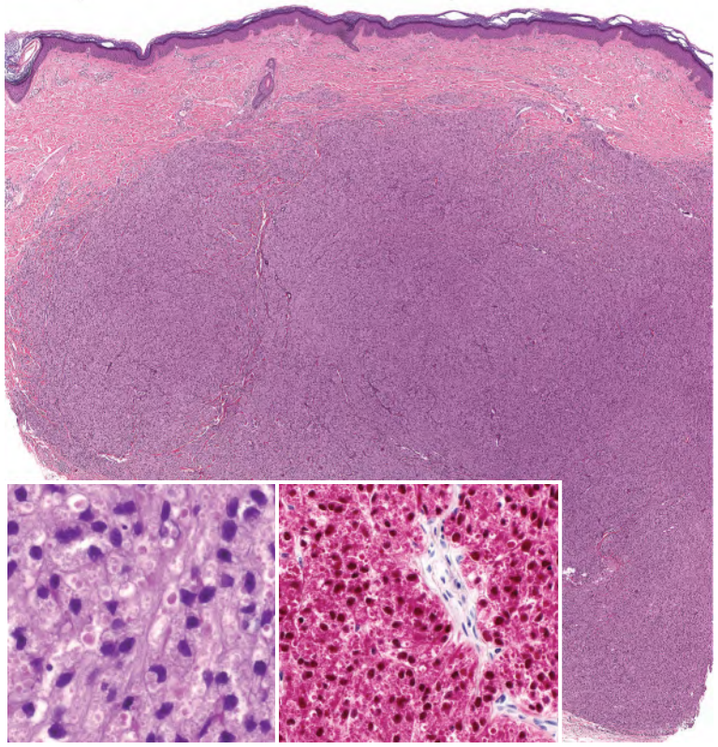

Fig. 115.14 Granular cell tumor. The tumor may show a nodular or infiltrative growth pattern. The large polygonal cells have finely granular cytoplasm, pustulo-ovoid bodies, and round nuclei (left inset) that stain positively for S100 (right inset). *Courtesy Lorenzo Cerroni, MD.*

True (neural) granular cell tumors express S100 protein, SOX10, PGP9.5 (neuron-specific peptide), and nerve growth factor receptor. The cells may stain positively for CD68 and NKI/C3, but are negative for the lineage-restricted histiocytic marker CD163 as well as melanocytic differentiation markers Melan-A and HMB-45. There may be diffuse nuclear reactivity for MITF and TFE3, posing a diagnostic challenge with *TFE3*-rearranged tumors and PEComas[58,59].

Differential Diagnosis

The clinical differential diagnosis of lingual lesions includes an irritation fibroma, verruca, and squamous cell carcinoma (SCC). Elsewhere, this tumor may resemble a dermatofibroma, regressing verruca, or adnexal neoplasm (see Table 115.2). Granular cell tumors can induce considerable pseudoepitheliomatous (pseudocarcinomatous) hyperplasia of the overlying epithelium, and superficial biopsy samples have been mistaken for SCC, especially on the tongue[60]. A variety of epithelial and mesenchymal neoplasms can show granular cell change, including BCCs, leiomyomas, dermatofibromas, and leiomyosarcomas[47].

Treatment

The treatment is complete excision. If incompletely excised, this tumor has a high local recurrence rate, due to the plexiform or perineurial growth pattern.

PERINEURIOMA

Synonyms: ▪ Storiform perineurial fibroma ▪ Fibrolamellar nerve sheath tumor ▪ Localized hypertrophic neuropathy

Introduction

Perineuriomas represent a proliferation of perineurial cells, with both intraneural and extraneural growth patterns. These tumors are rare and Table 115.5 outlines their features.

Downloaded for Anonymous User (n/a) at Egyptian Knowledge Bank from ClinicalKey.com by Elsevier on March 10, 2024. For personal use only. No other uses without permission. Copyright ©2024. Elsevier Inc. All rights reserved.

KEY FEATURES OF SOFT TISSUE (EXTRANEURAL) PERINEURIOMAS OF INTEREST TO DERMATOLOGISTS
Clinical features
• Solitary, nondescript, skin-colored, soft tissue mass • Occurs primarily on the trunk and extremities of adults, with the sclerosing variant favoring the hands of young men
Histopathologic features
• Predominant cell type is the perineurial cell, which is a modified fibroblastic cell • In classic soft tissue perineurioma, there is a well-circumscribed (but non-encapsulated) proliferation of slender, elongated spindle cells within the dermis and/or subcutis; the latter form tightly woven fascicles, sometimes with a lamellar or storiform pattern (Fig. 115.15), and the intertwining stroma can be hyalinized or myxoid • In the sclerosing variant, there may be epithelioid cells alternating with spindle cells, intermixed with thick collagen bundles • Reticular perineurioma, another variant, is characterized by a lace-like arrangement of cells that leads to the formation of microscopic cysts • Hybrid benign peripheral nerve sheath tumors may show a perineurial neoplastic population closely intermingled with a schwannomatous (or more rarely neurofibromatous) population • Only very infrequent atypical cases have significant atypia and/or increased mitotic activity
Immunohistochemistry
• Cells stain positively for EMA, GLUT1, and claudin-1 • CD34 may be positive (60% of cases); S100 protein and SOX10 are invariably negative (with the exception of hybrid benign peripheral nerve sheath tumors)
Clinical differential diagnosis
• Benign soft tissue tumors (e.g. lipoma) and soft tissue sarcomas
Histologic differential diagnosis
• Neurofibromas with extensive fibrosis (S100-, SOX10-, and NF-positive), DFSP (EMA-, GLUT1-, and claudin-1-negative; CD34-positive), sclerosing fibroma (EMA-, GLUT1-, and claudin-1-negative)
Treatment
• Complete excision – biologic behavior usually benign, rarely malignant

Table 115.5 Perineuriomas – key features of extraneural variants of interest to dermatologists. DFSP, dermatofibrosarcoma protuberans; EMA, epithelial membrane antigen; NF, neurofilament. Claudin-1 is a tight junction-associated protein. Based upon references 122, 123, & 124.

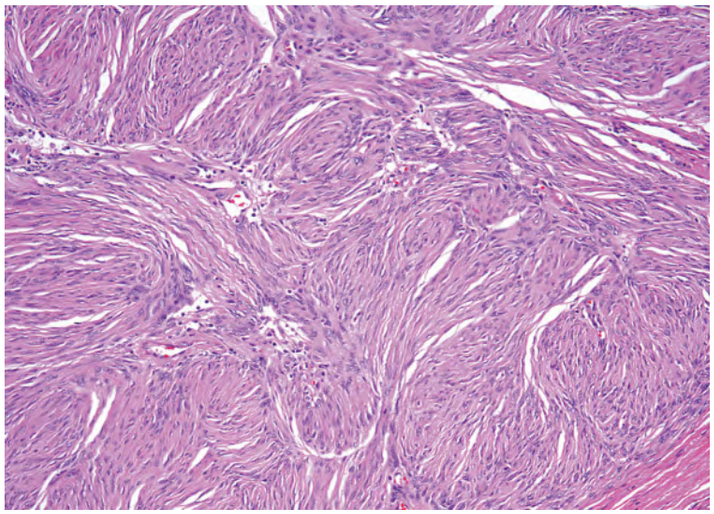

Fig. 115.15 Soft tissue perineurioma. Compact proliferation of spindle cells with lobular and storiform pattern.

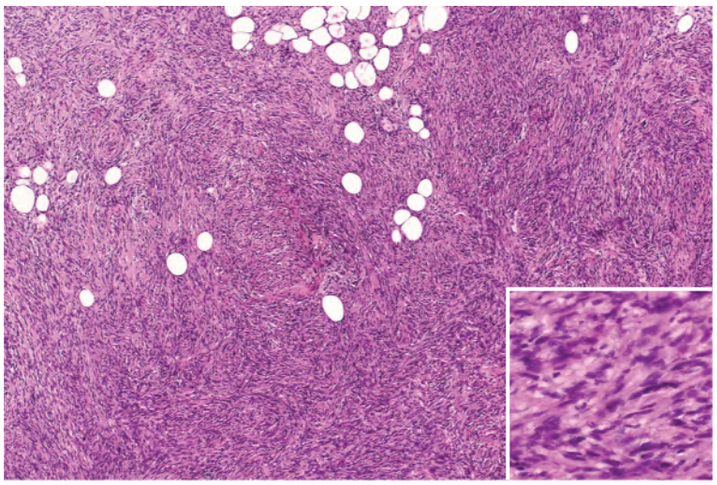

Fig. 115.16 Malignant peripheral nerve sheath tumor. Overall, the intersecting fascicles create a "herringbone" pattern. There is marked cellular pleomorphism with cytologic atypia and mitotic activity (inset). *Courtesy Lorenzo Cerroni, MD.*

MALIGNANT PERIPHERAL NERVE SHEATH TUMOR

Synonyms: ▪ Neurosarcoma ▪ Malignant schwannoma

The term "malignant peripheral nerve sheath tumor" (MPNST) is preferable to the widely used but confusing synonyms above. This is because any cellular component of the peripheral nerve can give rise to these tumors, including perineurial or endoneurial fibroblasts (rather than Schwann cells)[61,62]. MPNST is primarily a tumor of deep soft tissues and rarely involves the skin. Despite its rarity, MPNST has clinical relevance for dermatologists because this malignancy develops within 2%–30% of plexiform neurofibromas, which are associated with NF1[63] (see Ch. 61).

A definitive diagnosis requires histologic examination, usually in conjunction with immunohistochemistry and molecular biologic analysis. Histologically, in the most common form, there is a proliferation of atypical spindle cells, often arranged in a "herringbone" pattern. There is variable cytologic atypia, numerous abnormal mitotic figures, and areas of necrosis and hemorrhage (Fig. 115.16)[61,62]. Staining for S100 protein and SOX10, if positive, is only patchy or focal[51]. Regardless of the clinical setting (sporadic, NF1-associated, or radiotherapy-associated), MPNSTs show frequent and concurrent loss-of-function mutations in *NF1*, *CDKN2A/CDKN2B*, and the polycomb repressive complex 2 (PRC2)-related genes *EED* or *SUZ12*[63]. Complete loss of PRC2 activity and an associated lack of immunohistochemical expression of the epigenetic marker H3K27me3 (trimethylation of lysine 27 on histone H3 which represses transcription) are observed in >80% of high-grade MPNSTs and may represent a useful tool for its differentiation from other soft tissue sarcomas[64].

MERKEL CELL CARCINOMA

Synonyms: ▪ Primary neuroendocrine carcinoma of the skin ▪ Trabecular carcinoma of the skin ▪ Primary small cell carcinoma of the skin ▪ Cutaneous apudoma

Key features

- Predilection for the head and neck region of older adults
- Solitary, rapidly growing nodule
- Histologically, tumor is composed of small, round blue cells, often with a nested or trabecular growth pattern
- High mitotic rate, frequent single-cell or zonal necrosis, often perinuclear dot-like CK20-positivity (pathognomonic)
- Approximately 40% of patients develop local, nodal, or distant metastasis

Downloaded for Anonymous User (n/a) at Egyptian Knowledge Bank from ClinicalKey.com by Elsevier on March 10, 2024. For personal use only. No other uses without permission. Copyright ©2024. Elsevier Inc. All rights reserved.

Introduction

Merkel cell carcinoma (MCC) is an aggressive cutaneous carcinoma that shares ultrastructural and immunohistochemical features with other neuroendocrine tumors. Although rare, the incidence of MCC is rapidly increasing along with the aging population. These tumors display nonspecific clinical features and highly aggressive behavior. Early recognition and adequate therapy are therefore critical.

History

This tumor was originally described by Toker and given the name "trabecular carcinoma" based on its lattice-like and infiltrative growth pattern[65]. Subsequently, the neuroendocrine nature of this tumor was recognized. Similarities to the normal Merkel cell of the skin led to its name[66].

Epidemiology

The male:female ratio is 1.5:1 and its incidence increases strikingly with age, e.g. MCC is 10 000 times more likely to arise in an 80-year-old individual than in a 20-year-old[67]. Other risk factors include lightly pigmented skin, extensive sun exposure, and chronic immunosuppression (e.g. organ transplantation recipients, hematologic malignancies)[68].

Pathogenesis

The cells of MCC and the normal Merkel cell, a touch-sensing cell located in the basal layer of the epidermis, share several features. However, the MCC's cell of origin is unclear and it appears unlikely that normal Merkel cells give rise to this carcinoma[66]. This tumor is also referred to as "primary neuroendocrine carcinoma of the skin", a term that is often used in pathology reports.

In 2008, a landmark discovery revealed the association of MCC with a novel polyomavirus, now referred to as Merkel cell polyomavirus (MCPyV)[69]. In humans, this polyomavirus is ubiquitous as it can be readily detected within the normal skin of most healthy people where it exists in an episomal form. Very rarely, a clonal integration event leads to critical portions of the virus being spliced into a human chromosome, ultimately resulting in MCC. Of note, the integration event must be accompanied by mutation(s) that lead to truncation of the large T antigen and inactivation of its helicase domain. If not inactivated, the helicase domain would initiate DNA replication at the integration site which would then lead to cell death. Inhibition of viral oncoproteins in polyomavirus-infected tumor cells results in a cessation of proliferation, suggesting that ongoing viral protein expression is required for MCCs[70].

In the US, ~80% of MCCs are driven by this polyomavirus[71], while the remaining 20% are virus-negative. The latter tumors arise in chronically sun-damaged skin and contain very high numbers of UV-signature mutations[72]. Interestingly, only about 40% of MCCs in Australia are virus-induced, with the majority related to ultraviolet exposure. In contrast, in Asian countries, where people have more pigmented skin, 90% of MCCs are virus-driven.

Clinical Features

This cutaneous carcinoma can develop at any site, but favors the head and neck region, followed by the extremities and the buttocks. It usually presents as a pink–red to violaceous, firm, dome-shaped, solitary nodule that has grown rapidly (Fig. 115.17)[67]. Ulceration can occur. Overall, the behavior is that of an aggressive tumor, with significant risk of local, regional, and/or distant recurrence and metastasis.

In an analysis of 9387 cases of MCC, 65% of patients presented with local disease whereas 26% and 8% presented with nodal or distant metastases, respectively[73]. Prior to the advent of immunotherapy,

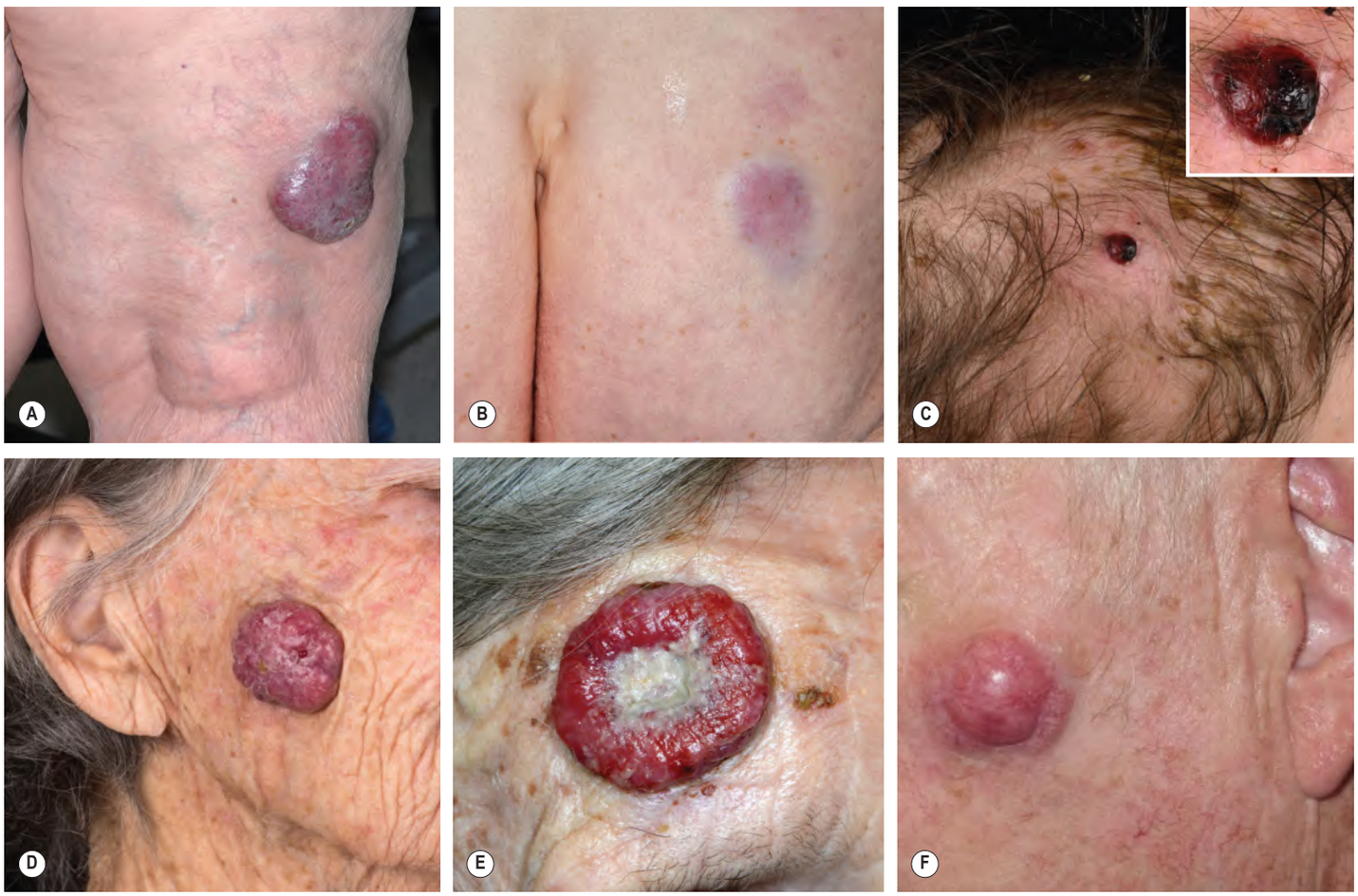

Fig. 115.17 Merkel cell carcinoma (primary neuroendocrine carcinoma of the skin). A Exophytic violet tumor on the posterior thigh; the clinical differential diagnosis included lymphoma. **B** Minimally elevated violaceous plaque with peripheral blue color arising within the sun-protected skin of the buttocks; the clinical differential diagnosis included a vascular tumor. **C** Hemorrhagic purple nodule within sun-damaged skin on the scalp. **D–F** Large pink to red nodules arising in older adults within obvious photodamaged skin. The lesions can have a lobulated surface, central ulceration, or telangiectasias. *A–E, Courtesy Department of Dermatology, University Graz.*

Downloaded for Anonymous User (n/a) at Egyptian Knowledge Bank from ClinicalKey.com by Elsevier on March 10, 2024. For personal use only. No other uses without permission. Copyright ©2024. Elsevier Inc. All rights reserved.

five-year overall survival for these three groups was 50% (local disease), 35% (nodal disease), and 15% (distant disease). Tumor diameter at the time of diagnosis influences prognosis, with lesions >2 cm (but without invasion of fascia) having a 40% overall survival at five years (compared to 55% for tumors ≤2 cm; Table 115.6)[73].

Occasionally, paraneoplastic syndromes, similar to those seen with other neuroendocrine carcinomas, occur in patients with MCC. These include malignancy-associated hyponatremia and Lambert–Eaton myasthenic syndrome.

Pathology

The tumor appears as a poorly defined dermal mass, often infiltrating the subcutaneous fat, fascia, and even muscle. While it may show various growth patterns, a sheet-like growth pattern is seen most commonly, followed by nested and trabecular patterns (Fig. 115.18A)[74]. Characteristically, the edge of the tumor shows a trabecular infiltrating pattern[65]. The tumor is composed of monotonously uniform, small, round to oval cells that are about two to three times larger than mature lymphocytes[65,66]. Their cytoplasm is scant and faintly amphophilic. The nuclei of these cells are ovoid with a finely dispersed chromatin pattern and distinct nuclear membranes (Fig. 115.18B). Nucleoli are usually not prominent, but mitotic figures are abundant. Extensive areas of necrosis, individual cell necrosis, and characteristic crush or drying artifacts are common[74]. Intralymphatic involvement by tumor cells is not uncommon, sometimes distant from the main tumor mass. In some cases, single neoplastic cells or tiny aggregates are present at the edge of the biopsy specimen, rendering evaluation of the surgical margin difficult without the aid of immunohistochemistry (see below).

Various types of differentiation have been described in MCC, including rosette-like structures resembling Homer Wright rosettes of neuroblastoma, epidermotropic involvement with pagetoid spread, and eccrine and squamoid differentiation[75,76]. Immunohistochemically, there is a characteristic perinuclear globule upon staining for low-molecular-weight cytokeratins (CK) such as CK20, CK5/6, and CK7 (Fig. 115.18C). This corresponds to the ultrastructural distribution of paranuclear whorls of intermediate filaments[74,75]. In addition, there is positive staining for various neuroendocrine markers, including chromogranin, synaptophysin, somatostatin, calcitonin, and vasoactive intestinal peptide[75]. These peptides are associated with ultrastructurally demonstrable, membrane-bound, dense-core secretory granules.

The tumor also expresses neuron-specific enolase and occasionally neural filaments, CD56, and CD99; however, immunostaining for S100 protein is characteristically negative[75]. Likewise, a negative reaction for thyroid transcription factor 1 (TTF-1) helps to differentiate MCC from cutaneous metastases of other small cell carcinomas (pulmonary and extrapulmonary); the latter are characteristically positive for this marker[75]. Recognition of MCPyV, which can be detected by immunohistochemical (e.g. T antigen) and molecular biologic methods[77], provides an additional tool for diagnosis; however, false-positive PCR results are possible given the ubiquitous nature of the virus. For prognostication, increased p63 expression may portend clinically aggressive behavior, but to date has not altered prognosis based upon stage (Table 115.6)[78]. Negativity for MCPyV may associated with a somewhat poorer prognosis, whereas ALK-positive MCC (which is usually accompanied by MCPyV positivity) appears to have a less aggressive behavior[72,79]. A dataset for the reporting of MCCs has recently been proposed[79a].

Differential Diagnosis

The differential diagnosis of early-stage MCCs includes keratinocyte carcinomas, epidermoid cysts, adnexal tumors, and amelanotic melanoma. When tumors are violaceous or hemorrhagic, the differential

MERKEL CELL CARCINOMA – 8TH AJCC STAGING SYSTEM				
Stage		**Primary tumor**	**Lymph node**	**Distant metastasis**
0		*In situ* (only within the epidermis)	No regional lymph node metastasis	No
I	Clinical*	≤2 cm maximum tumor dimension	Nodes negative by clinical examination (no pathologic examination performed)	No
I	Pathologic†	≤2 cm maximum tumor dimension	Nodes negative by pathologic examination	No
IIA	Clinical	>2 cm tumor dimension	Nodes negative by clinical examination (no pathologic examination performed)	No
IIA	Pathologic	>2 cm tumor dimension	Nodes negative by pathologic examination	No
IIB	Clinical	Primary tumor invades bone, muscle, fascia, or cartilage	Nodes negative by clinical examination (no pathologic examination performed)	No
IIB	Pathologic	Primary tumor invades bone, muscle, fascia, or cartilage	Nodes negative by pathologic examination	No
III	Clinical	Any size/depth tumor	Nodes positive by clinical examination (no pathologic examination performed)	No
IIIA	Pathologic	Any size/depth tumor	Nodes positive by pathologic examination only (nodal disease not apparent by clinical examination)	No
		Not detected ("unknown primary")	Nodes positive by clinical examination; confirmed by pathologic examination	No
IIIB	Pathologic	Any size/depth tumor	Nodes positive by clinical examination and confirmed by pathologic examination – *or* – In-transit metastasis‡	No
IV	Clinical	Any	Regional nodal involvement +/–	Distant metastasis detected clinically
IV	Pathologic	Any	Regional nodal involvement +/–	Distant metastasis confirmed by pathologic examination

*Clinical detection of nodal or metastatic disease may be via inspection, palpation, and/or imaging.
†Pathologic detection/confirmation of nodal disease may be via sentinel lymph node biopsy and pathologic confirmation of metastatic disease may be via biopsy of the suspected metastasis.
‡In-transit metastasis: a tumor distinct from the primary lesion and located either: (1) between the primary lesion and the draining regional lymph nodes; or (2) distal to the primary lesion.

Table 115.6 Merkel cell carcinoma – 8th American Joint Committee on Cancer (AJCC) staging system. While more extensive lymph node involvement portends a poorer prognosis, the number of positive lymph nodes is not factored into the staging of MCC. *Adapted from www.merkelcell.org/staging and Harms KL, Healy MA, Nghiem P, et al. Analysis of prognostic factors from 9387 Merkel cell carcinoma cases forms the basis for the new 8th edition AJCC staging system. Ann Surg Oncol 2016;23:3564–71.*

Downloaded for Anonymous User (n/a) at Egyptian Knowledge Bank from ClinicalKey.com by Elsevier on March 10, 2024. For personal use only. No other uses without permission. Copyright ©2024. Elsevier Inc. All rights reserved.

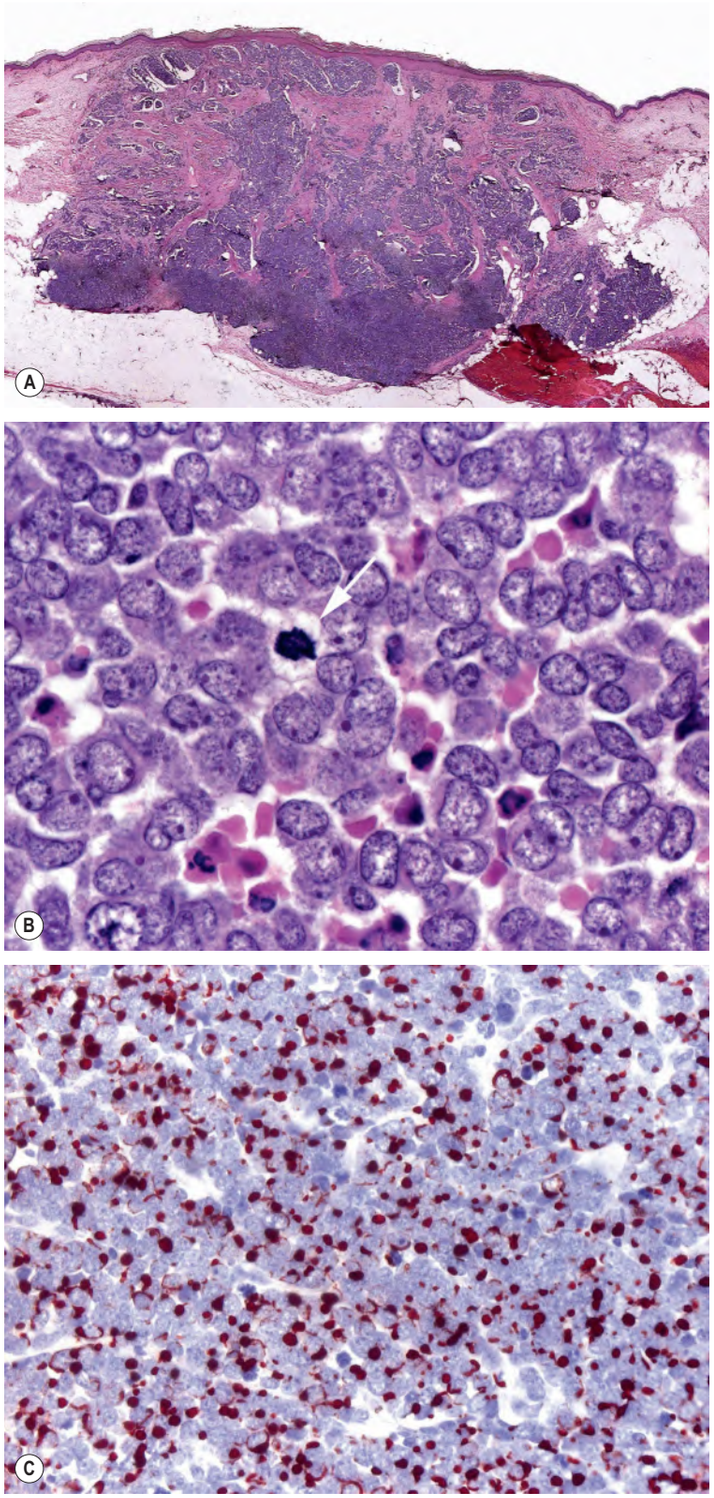

Fig. 115.18 Merkel cell carcinoma (primary neuroendocrine carcinoma of the skin). A Nodular infiltrate of basaloid cell aggregates and strands throughout the dermis, extending into the superficial subcutis. **B** Small, round to ovoid basaloid cells with vesicular nuclei and small nucleoli; note several necrotic (apoptotic) cells and a mitotic figure (white arrow). **C** Immunohistochemical stain for cytokeratin 20 demonstrates a characteristic perinuclear dot pattern. *Courtesy Lorenzo Cerroni, MD.*

diagnosis also includes pyogenic granuloma, hemangioma, angiosarcoma, and lymphoma (see Fig. 115.17A–C). Histologically, there is a broad spectrum of small, round, blue cell tumors of diverse histogenesis that can be confused with MCC[75]. These include metastatic neuroendocrine carcinoma of the lung (small cell or oat cell carcinoma), poorly differentiated eccrine carcinoma, lymphoma, metastatic neuroblastoma, primary peripheral primitive neuroectodermal tumor, Ewing sarcoma, melanoma, and poorly differentiated SCC[74,75].

Treatment

For newly diagnosed locoregional MCC, surgery remains the principal initial therapy. Excision of the primary tumor plus sentinel lymph node biopsy (SLNB) are recommended for most patients (Fig. 115.19), with these procedures also providing prognostic information[80–82]. SLNB positivity at the time of the initial MCC diagnosis is estimated to be 35%[83]. Age >65 years, immunosuppression, primary tumor on the trunk, and larger tumor size are associated with higher rates of SLN positivity[83,84]. However, even tumors ≤5 mm are associated with a positive SLNB in ~15% of patients[83]. Surgery is often followed by radiation therapy to the primary site and in some patients, the draining lymph node basin (see Fig. 115.19).

The management of MCC often requires a multidisciplinary approach with involvement of surgeons, medical and radiation oncologists, and dermatologists. Updated guidelines are readily available[85] and Fig. 115.19 provides a current algorithm for evaluation and treatment[86–93].

Prior to the advent of immunotherapy, cytotoxic chemotherapy was the primary option for advanced stage disease, but responses were not durable[94]. Several clinical trials, in which anti-PD-1 and anti-PD-L1 antibodies demonstrated significantly improved progression-free survival and overall survival compared to historical data for conventional chemotherapy[90–93,93a], led to FDA approval of avelumab, pembrolizumab, and retifanlimab. These antibodies are now considered first-line therapies for advanced MCC[85]. However, primary or acquired resistance to immunotherapy remains a major challenge, ultimately affecting >50% of treated patients[90–93,93b].

Careful surveillance is important because MCC recurs in up to 40% of patients[95] and effective treatments are now available. A baseline determination (within a few months of initial therapy) of the presence or absence of circulating antibodies against the Merkel virus oncoprotein is recommended[96]. In seropositive patients, antibody titers correlate with tumor burden and represent a sensitive and specific assay that can be followed longitudinally[96,97]. However, ~50% of patients do not produce these antibodies[96,97] and surveillance via imaging is required in these seronegative patients. The latter group may have an ~40% higher risk of recurrence compared to seropositive patients of the same stage.

Over 80% of recurrences of MCC arise within the first 3 years after diagnosis[95]. There is a web-based recurrence risk calculator (merkelcell.org/recur) that factors in stage as well as the disease-free interval since treatment, immune status, sex, age, and location of the primary site. This calculator provides an accurate assessment of a patient's ongoing risk of recurrence and assists in planning frequency of surveillance testing.

HETEROTOPIC NEURAL TISSUE OF THE SKIN

These rare lesions develop from embryologically misplaced neural tissue within the skin.

Nasal Glial Heterotopia

Synonyms: ▪ Nasal glioma ▪ Nasal neuroglial heterotopia ▪ Nasal heterotopic brain tissue

Key features

- Rare, benign, congenital lesion
- Most common near the root of the nose, but can be intranasal
- Solitary, firm, smooth, skin-colored to red–purple papulonodule
- Microscopically, lobulated neuroglial tissue

History

The term "nasal glioma" was introduced by Schmidt in 1900.

Epidemiology

These extracranial rests of brain tissue are rare and usually manifest at the time of birth.

Pathogenesis

Nasal glial heterotopia (NGH) is the result of embryologic displacement of brain tissue, usually along the cranial closure lines and without apparent communication with underlying structures (see Figs. 64.1 & 64.8)[98]. It has

Downloaded for Anonymous User (n/a) at Egyptian Knowledge Bank from ClinicalKey.com by Elsevier on March 10, 2024. For personal use only. No other uses without permission. Copyright ©2024. Elsevier Inc. All rights reserved.

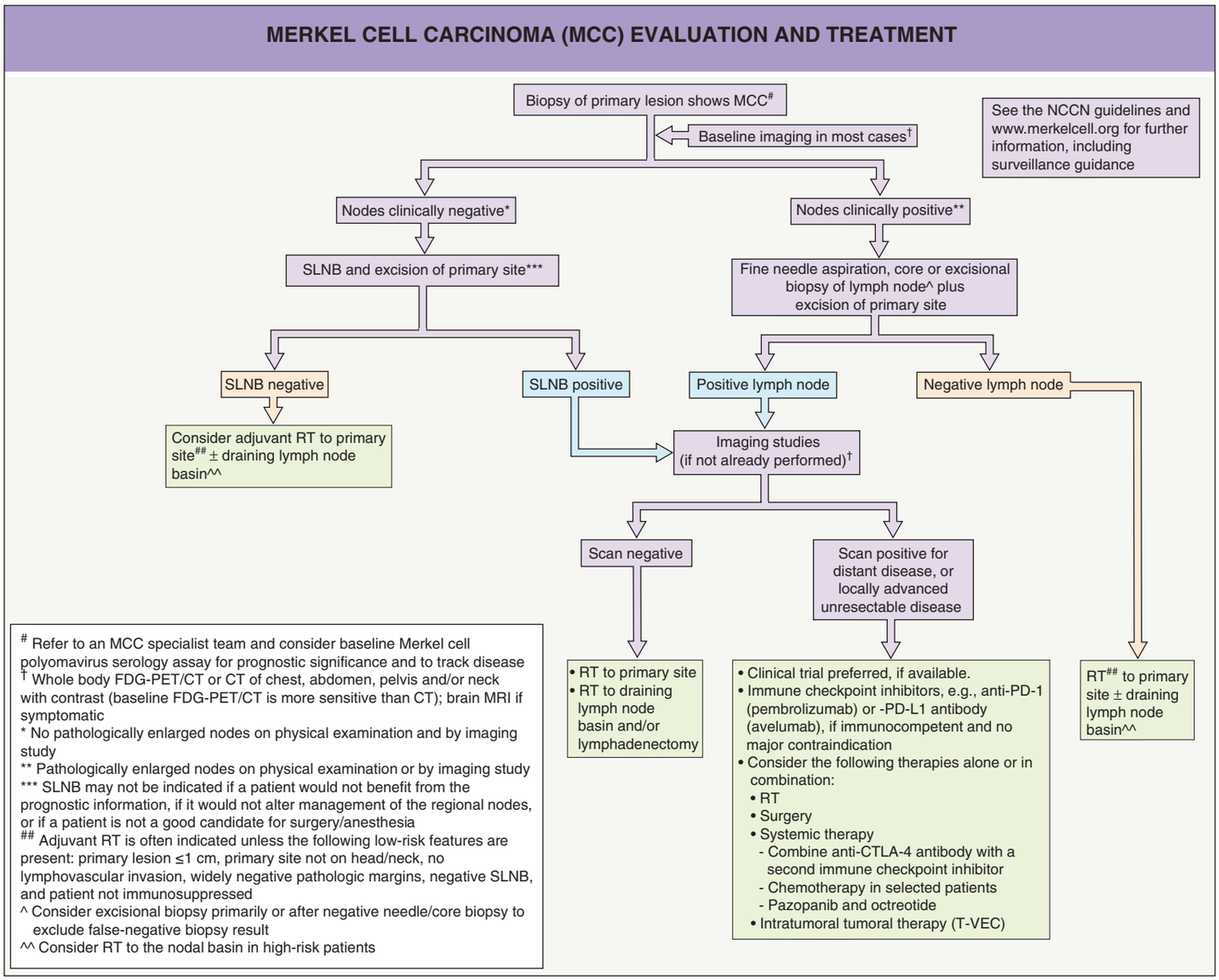

Fig. 115.19 Merkel cell carcinoma (MCC) evaluation and treatment algorithm. CT, computerized tomography; FDG-PET, fluorodeoxyglucose-positron emission tomography; NCCN, National Comprehensive Cancer Network; RT, radiotherapy; SLNB, sentinel lymph node biopsy.

a predilection for the perinasal area; therefore, it is commonly referred to as a nasal "glioma". As this is not a true neoplasm, the term is misleading[99].

Clinical features

NGHs are firm, smooth-surfaced, skin-colored to red–violet papulonodules that may have obvious telangiectasias and range in size from 1 to 3 cm. Approximately 60% are located on the bridge of the nose (Fig. 115.20), with the remainder usually located intranasally or in both locations[99,100].

Fig. 115.20 Nasal glial heterotopia ("nasal glioma") in a newborn. Pink to violet soft nodule.

Pathology

In a NGH, an ill-defined, non-encapsulated neuropil-like mass is seen within the dermis and subcutis. The neuropil-like tissue is composed of nests and strands of pale-staining, finely vacuolated or fibrillary matrix in which various types of astrocytes can be found[98]. Gemistocytic astrocytes, with polygonal, eosinophilic cytoplasm and eccentric nuclei, as well as multinucleated giant cells, are relatively common. Mature neurons are present in variable numbers[99]. Occasionally, residual meningoendothelial cells, ependymal cells, choroid plexus-like structures, and pigmented cells can be identified[100]. No mitotic activity or aggressive growth pattern has been described.

Differential diagnosis

Clinically, the lesion must be differentiated from other facial midline lesions (see Ch. 64)[99,101] as well as an infantile hemangioma, dermoid cyst, and nasal polyp (see Table 64.1).

Treatment

Most cutaneous neural malformations can be effectively treated by excision. Cranial imaging is recommended before these lesions are biopsied or removed[102], because NGHs can communicate with the

Downloaded for Anonymous User (n/a) at Egyptian Knowledge Bank from ClinicalKey.com by Elsevier on March 10, 2024. For personal use only. No other uses without permission. Copyright ©2024. Elsevier Inc. All rights reserved.

intracranial space, and therefore cerebrospinal fluid leakage and subsequent meningoencephalitis and other neurologic damage may occur after biopsy[99].

Heterotopic Meningeal Tissue

Synonym: ▪ Rudimentary meningocele

Key features

- Rare disorder that usually presents in neonates and infants and favors the scalp, forehead, and dorsal midline
- Soft to firm, skin-colored nodule, often with partial alopecia and/or the "hair collar" sign when on the scalp
- Can be associated with other developmental anomalies
- Histologically, solid nests and strands, whorls of epithelioid or spindle cells, and psammoma bodies

History

The concept of rudimentary meningocele was introduced by Lopez et al.[103].

Epidemiology

Meningeal heterotopias are rare lesions, usually apparent at or shortly after birth[103].

Pathogenesis

Rudimentary meningoceles are thought to result from herniation of the meningeal lining into the skin and subcutaneous tissues during embryologic development, usually with no residual communication with the CNS (see Fig. 64.8)[104]. Although these lesions are sometimes classified as type I cutaneous meningiomas[103], considering their non-neoplastic nature, they are better classified as rudimentary meningoceles[104].

Clinical features

Rudimentary meningoceles most commonly present on the scalp of neonates and infants at the sites of cranial closure (see Fig. 64.1). Less often they occur on the forehead (midline) or overlie the spine. Skin-colored papules or nodules on the scalp are often associated with alopecia and/or the "hair collar" sign[105].

Pathology

A rudimentary meningocele is an ill-defined mass of cavernous, pseudovascular spaces embedded in a markedly collagenous stroma[104,106]. The spaces may be lined by elongated meningoendothelial cells characterized by eosinophilic cytoplasm, round or ovoid nuclei, and a fine chromatin pattern. Similar cells dissect or wrap around collagen fibers, producing "collagen bodies". No significant cytologic atypia or mitotic activity is present. Focal calcification and psammoma bodies (eosinophilic laminated and whorled structures with variable calcification) may occur. Meningothelial cells consistently express vimentin and EMA, whereas immunoexpression of S100 protein is variable.

Differential diagnosis

In neonates and infants, rudimentary meningoceles must be distinguished from "atretic" meningoceles (an intermediate form with an intracranial connection), membranous aplasia cutis congenita, heterotopic brain tissue, dermoid cysts, and infantile hemangiomas. Type II and type III meningiomas are in the histologic differential diagnosis. They usually develop on the scalp of adults, either along the course of a cranial nerve (type II) or as a cutaneous "metastasis" or direct extension of a primary meningioma of the arachnoid lining (type III)[103,105,107]. Within the deep dermis or subcutis, there is a multinodular mass, often with an infiltrative growth pattern[108–110]. The cells may show a variable degree of differentiation, and in the most common form, the spindle cells have a concentric, whorl-like arrangement[108]; psammoma bodies are often present[108–110]. Mitotic figures are rare in type II and variably increased in type III. Clinically, these nodular tumors may have associated alopecia and can resemble an epidermoid or pilar cyst, adnexal tumor, or cutaneous metastasis. They may occur in the setting of neurofibromatosis (types I and II)[111]. Lastly, the deeper portions of rudimentary meningoceles may have an infiltrative growth pattern with pseudovascular spaces, with a resemblance to angiosarcoma.

Treatment

As with nasal glial heterotopia, imaging studies are required prior to biopsy or excision. The latter is performed primarily by neurosurgeons.

PRIMITIVE NEUROECTODERMAL TUMORS

Synonyms: ▪ Neuroblastoma (primary or metastatic) ▪ Neuroepithelioma ▪ Ganglioneuroma

Key features

- The third most common malignant neoplasm in children
- Cutaneous metastases (children) are seen more frequently than primary cutaneous tumors (adults)
- Cutaneous metastases present as multiple, blue to purple dermal nodules in association with elevated serum and urine catecholamines
- Histologically, small, round, blue cells in a nested or infiltrative growth pattern, with formation of Homer Wright rosettes
- Prognosis depends on the patient's age, clinical stage, and specific genetic abnormalities (e.g. *MYCN* oncogene amplification)

Introduction

Neuroblastic–ganglionic tumors are derived from the germinal neuroepithelium and/or from the neural crest. They display a wide spectrum of clinicopathologic features based on their relative degree of differentiation, ranging from very primitive neuroectodermal tumors to more mature forms such as neuroblastomas.

History

The concept of neuroectodermal tumors was introduced by Stout in 1918. Since then, different terms have been used for tumors with cytologically similar features, reflecting the controversy regarding this entity. Dehner performed a comprehensive review of the nosology of this diverse group of lesions, suggesting the term "primitive neuroectodermal tumors" (PNET)[112]. This concept was then further expanded following the recognition that PNET and extraosseous Ewing sarcoma can have similar immunohistochemical and chromosomal abnormalities (e.g. translocations involving *EWSR1*), and therefore nowadays they are considered within the same neoplastic spectrum[113].

Epidemiology

Neuroblastoma is the third most commonly observed childhood malignancy, and cutaneous metastases are frequent[3]. Most neuroblastomas develop as sporadic tumors, although familial cases have been reported. Primary cutaneous PNETs are tumors of adulthood (mean age, 40 years) and are exceedingly rare[3]. Cutaneous ganglioneuroma has a predilection for the trunk.

Pathogenesis

PNETs of the skin either represent metastases from a PNET of the adrenals and/or ganglionic chain (traditionally designated as neuroblastomas) or develop *de novo* from heterotopic neural crest cells[2]. In the latter case, they are referred to as peripheral PNETs or as peripheral neuroblastomas. *ALK* is implicated in the tumorigenesis of many familial and some sporadic cases of neuroblastoma. In addition, DNA ploidy and specific genetic abnormalities, such as *MYCN* oncogene amplification or aberrations of chromosomes 11q or 1p, influence prognosis[114]. Cutaneous ganglioneuroma is best regarded as resulting from abnormal migration and differentiation of neural crest cells.

Downloaded for Anonymous User (n/a) at Egyptian Knowledge Bank from ClinicalKey.com by Elsevier on March 10, 2024. For personal use only. No other uses without permission. Copyright ©2024. Elsevier Inc. All rights reserved.

Clinical Features

In children, the cutaneous metastases of neuroblastoma often manifest as multiple, blue to purple, dermal papules or nodules that resemble the "blueberry muffin" lesions seen with congenital infections or hematologic disorders[4] (see Ch. 121). These nodules may blanch upon stroking and develop an erythematous halo[115,116]. Serum and urine catecholamine levels are typically elevated. In children, complete spontaneous regression has been described in stage IV-S neuroblastoma, including cutaneous metastases[117].

In adults, PNETs are rapidly growing dermal or subcutaneous nodules that favor the trunk or head. Ulceration is common. These highly aggressive neoplasms have an almost invariably fatal outcome.

Pathology

In metastatic neuroblastoma, an ill-defined or infiltrative mass is present in the dermis and/or the subcutis. However, when smaller and more superficial, deposits are more defined. The tumor mass is composed of atypical, small, dark cells with scant cytoplasm[2,112]. The cells have larger nuclei than mature lymphocytes (with a coarse chromatin pattern) and they form irregular nests, cords, or poorly cohesive sheets. Rosette formation, by concentrically arranged tumor cells in double or multiple circles, is common. The center of the rosettes contains converging fine fibrillary material characteristic of Homer Wright-type rosettes[2] (Fig. 115.21). Mitotic activity is high, and abnormal mitoses are abundant. Extensive areas of necrosis and hemorrhage are common.

As the tumor differentiates, the relative proportion of neuroblastoma components decreases, and the ganglioneuromatous elements increase. Eventually, the tumor may show features indistinguishable from a ganglioneuroma[117]. Cutaneous ganglioneuromas are characterized by mature ganglion cells immersed in a Schwann cell-rich stroma. Lesions consisting of only ganglion cells may also occur and are referred to as "ganglion cell choristomas". Ganglion cells are round-to-polygonal with vesicular nuclei and abundant pale cytoplasm; the latter contains Nissl granules which may be highlighted by a toluidine blue stain. Immunohistochemically, the cells of neuroblastomas and ganglioneuromas react variably with neural and neuroendocrine markers, depending on their state of differentiation. These markers include neuron-specific enolase, S100 protein, neurofilaments, synaptophysin, chromogranin, and CD99 (see Ch. 0)[114].

Primary cutaneous PNETs have similar histopathologic features to those of the classic neuroblastoma, but ganglionic or neuromatous differentiation is not characteristic. These two tumors also share major immunohistochemical features. However, MIC-2(013) is commonly expressed by PNETs, but not by neuroblastomas, facilitating their distinction[114,117–120].

Differential Diagnosis

In children, the clinical differential diagnosis includes other types of cutaneous metastasis, extramedullary hematopoiesis, and mastocytosis, whereas in adults it includes adnexal tumors, lymphoma, and soft tissue sarcomas. Histologically, both metastatic neuroblastoma and primary cutaneous PNET must be differentiated from other small, round, blue cell tumors that form rosettes and may involve the skin[120,121] (see discussion in MCC section). Cutaneous ganglioneuroma must be distinguished from cutaneous metastases of neuroblastoma, with age of onset and other clinical history required for distinction.

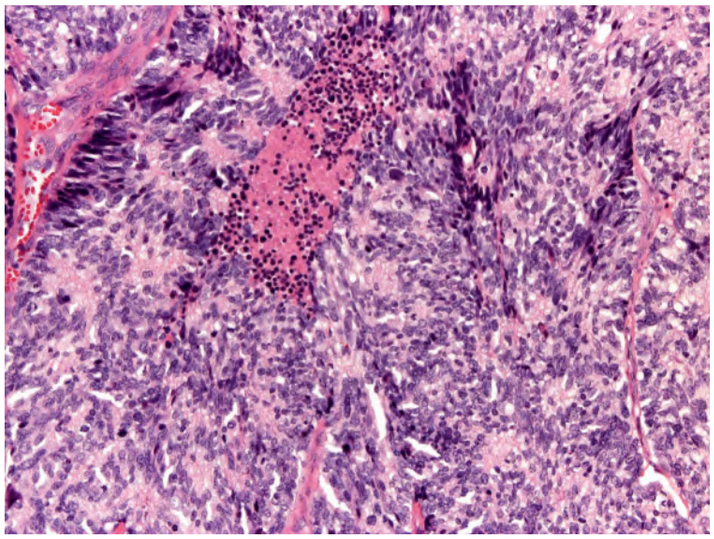

Fig. 115.21 Cutaneous neuroblastoma. The tumor is composed of small cells with small, round to ovoid nuclei that can be arranged in rosettes. The fibrillary material in the center of Homer Wright-type rosettes is characteristic. In the upper mid-portion of the figure there is a large area of necrosis. *Courtesy Lorenzo Cerroni, MD.*

Treatment

The effective treatment of neuroblastoma requires an interdisciplinary team that includes oncologists, surgeons, and radiation therapists. The overall prognosis of localized tumor involvement has improved with combined surgical excision, multiagent chemotherapy, differentiating agents (e.g. 13-cis-retinoic acid), immunotherapy (e.g. dinutuximab), hematopoietic stem cell transplantation, and radiopharmaceuticals[114]. Important prognostic factors include the age, stage, histologic differentiation, specific genetic abnormalities (e.g. *MYCN* oncogene amplification, 11q aberration), and response to initial chemotherapy[2].

Additional figures and table on Tumors and tumor-like conditions of ectopic and heterotopic neural tissue involving the skin, available in our eBook (see inside front cover for access code).

REFERENCES

1. Cates JM, Coffin CM. Neurogenic tumors of soft tissue. *Pediatr Dev Pathol*. 2012;15:62–107.
2. Goldblum JR, Folpe AL, Weiss SW. *Benign Tumors of Peripheral Nerves. Enzinger & Weiss's Soft Tissue Tumors*. 7th ed. Philadelphia: Elsevier; 2020:885–958.
3. Rodriguez FJ, Folpe AL, Giannini C, et al. Pathology of peripheral nerve sheath tumors: diagnostic overview and update on selected diagnostic problems. *Acta Neuropathol*. 2012;123:295–319.
4. Reed RJ, Fine RM, Meltzer HD. Palisaded, encapsulated neuromas of the skin. *Arch Dermatol*. 1972;106:865–870.
5. Argenyi ZB, Santa Cruz D, Bromley C. Comparative light-microscopic and immunohistochemical study of traumatic and palisaded, encapsulated neuromas of the skin. *Am J Dermatopathol*. 1992;14:504–510.
6. Höke A. Mechanisms of disease: what factors limit the success of peripheral nerve regeneration in humans? *Nat Clin Pract Neurol*. 2006;2:448–454.
7. Matthews GJ, Osterholm JL. Painful traumatic neuromas. *Surg Clin North Am*. 1972;51:1313–1324.
8. Burtner DD, Goodman M. Traumatic neuroma of the nose. *Arch Otolaryngol*. 1972;103:108–109.
9. Shapiro L, Juklin EA, Brownstein HM. Rudimentary polydactyly. *Arch Dermatol*. 1973;108:223–225.
10. Leblebici C, Savli TC, Yeni B, et al. Palisaded encapsulated (solitary circumscribed) neuroma: a review of 30 cases. *Int J Surg Pathol*. 2019;27:506–514.
11. Argenyi ZB. Immunohistochemical characterization of palisaded encapsulated neuroma. *J Cutan Pathol*. 1990;17:329–335.
12. Argenyi ZB, Cooper PH, Santa Cuz D. Plexiform and other unusual variants of palisaded encapsulated neuroma. *J Cutan Pathol*. 1993;20:34–39.
13. Argenyi ZB. Newly recognized neural neoplasms relevant to the dermatopathologist. *Dermatol Clin*. 1992;10:219–234.
14. Requena L, Grosshans E, Kutzner H, et al. Epithelial sheath neuroma; a new entity. *Am J Surg Pathol*. 2000;24:190–196.
15. Stout AP. The peripheral manifestations of specific nerve sheath tumor (neurilemoma). *Am J Cancer*. 1935;24:751–796.
16. Halliday D, Parry A, Evans DG. Neurofibromatosis type 2 and related disorders. *Curr Opin Oncol*. 2019;31:562–567.
17. Plotkin SR, Wick A. Neurofibromatosis and schwannomatosis. *Semin Neurol*. 2018;38:73–85.
18. Hulsebos TJM, Plomp AS, Wolterman RA, et al. Germline mutations of *INII/SMARCB1* in familial schwannomatosis. *Am J Hum Genet*. 2007;80:805–810.
19. Piotrowski A, Xie J, Liu YF, et al. Germline loss-of-function mutations in LZTR1 predispose to an inherited disorder of multiple schwannomas. *Nat Genet*. 2014;46:182–187.
20. Torres-Mora J, Dry S, Li X, et al. Malignant melanotic schwannian tumor: a clinicopathologic, immunohistochemical, and gene expression profiling study of 40 cases, with a proposal for the reclassification of "melanotic schwannoma". *Am J Surg Pathol*. 2014;38:94–105.
21. Sainz J, Huynh PD, Figueroa K, et al. Mutations of the neurofibromatosis type 2 gene and lack of the gene product in vestibular schwannomas. *Hum Mol Genet*. 1994;3:885–891.
22. Agnihotri S, Jalali S, Wilson MR, et al. The genomic landscape of schwannoma. *Nat Genet*. 2016;48:1339–1348.
23. Das Gupta TK, Brasfield RD, Strong EW, et al. Benign solitary schwannomas (neurilemomas). *Cancer*. 1969;24:355–366.

Downloaded for Anonymous User (n/a) at Egyptian Knowledge Bank from ClinicalKey.com by Elsevier on March 10, 2024. For personal use only. No other uses without permission. Copyright ©2024. Elsevier Inc. All rights reserved.

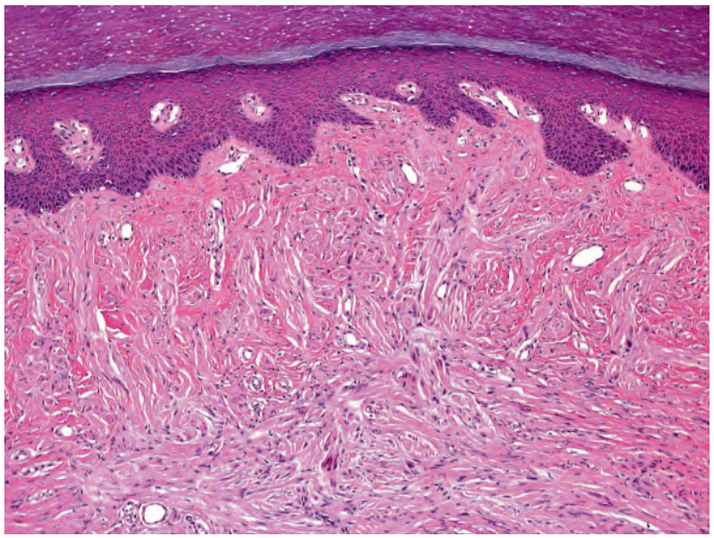

eFig. 115.1 Amputation neuroma (digit). Note the proliferation of nerve fascicles within a fibrotic stroma and the lack of bony structures. *Courtesy Lorenzo Cerroni, MD*.

eFig. 115.2 Mosaic form of neurofibromatosis type 1. Multiple pink–brown papules in a linear arrangement. *Courtesy Kalman Watsky, MD*.

eFig. 115.3 Plexiform neurofibromas. The pink–brown plaques are soft, and large lesions often have a sagging bag-like appearance. *Courtesy Julie V. Schaffer, MD*.

eFig. 115.4 Plexiform neurofibroma in a child with neurofibromatosis type 1. Pendulous, bag-like mass with overlying patches of hyperpigmentation.

Downloaded for Anonymous User (n/a) at Egyptian Knowledge Bank from ClinicalKey.com by Elsevier on March 10, 2024. For personal use only. No other uses without permission. Copyright ©2024. Elsevier Inc. All rights reserved.

eFig. 115.5 Merkel cell carcinomas (primary neuroendocrine carcinomas). A A rapidly growing, violaceous nodule on the toe. **B** Large, eroded, erythematous nodule arising within sun-damaged skin of the cheek. *B, Courtesy Lorenzo Cerroni, MD*.

eFig. 115.6 Merkel cell carcinoma (primary neuroendocrine carcinoma). A red–violet nodule arising within sun-damaged skin of the left fifth finger in a 70-year-old man.

TUMORS AND TUMOR-LIKE CONDITIONS OF ECTOPIC AND HETEROTOPIC NEURAL TISSUE INVOLVING THE SKIN				
	Nasal glial heterotopia ("nasal glioma")*	**Rudimentary meningocele**	**Cutaneous meningioma (types II and III)**	**Peripheral neuroblastoma**
Incidence	Rare	Rare	Extremely rare	Extremely rare
Age	Neonates	Neonates or infants	Usually adults	Late adulthood
Location	Most commonly near the root of the nose but can be intranasal	Scalp, forehead, paravertebral area	Scalp	Head and trunk
Size	1.0–3.0 cm	0.5–3.0 cm	0.5–4.0 cm	0.5–5.0 cm
Clinical appearance	Firm, smooth, skin-colored to red–purple nodule	Soft to firm nodule, often with alopecia or the "hair collar" sign; occasionally cystic; blue–red hue common	Soft to firm nodule, often with alopecia	Soft, skin-colored to red, often ulcerated nodule
Clinical differential diagnosis	Infantile hemangioma, nasal polyp, juvenile xanthogranuloma, dermoid cyst	Membranous aplasia cutis, heterotopic brain tissue, dermoid cyst, infantile hemangioma	Epidermoid or pilar cyst, adnexal tumors, cutaneous metastasis	Adnexal tumors, lymphoma, soft tissue sarcoma, cutaneous metastasis
Associations	Intracranial connection in ~20% ("atretic" encephalocele)	An intracranial connection may be present ("atretic" meningocele)	May be associated with neurofibromatosis (types I and II)	NA
Other	NA	NA	Metastasis of CNS meningioma must be excluded	Metastasis of ganglionic or adrenal neuroblastoma and extension of olfactory neuroblastoma must be excluded, especially in children
Histopathologic features	Lobulated neural tissue (glial cells, astrocytes, rarely true neurons)	Cystic or cavernous spaces, scattered meningothelial cells, pseudovascular pattern, psammoma bodies	Solid nests and strands, whorls of epithelioid or spindle cells, psammoma bodies	Rosette-like (Homer Wright-type) structures of small, round, blue cells, extensive infiltration and necrosis
Biologic course	Benign	Benign	Locally aggressive and destructive	Extremely malignant with widespread metastases

*Heterotopic brain tissue can also be located in the midline scalp, orbit, lip, and oropharynx.

eTable 115.1 Tumors and tumor-like conditions of ectopic and heterotopic neural tissue involving the skin.

Downloaded for Anonymous User (n/a) at Egyptian Knowledge Bank from ClinicalKey.com by Elsevier on March 10, 2024. For personal use only. No other uses without permission. Copyright ©2024. Elsevier Inc. All rights reserved.